



An Intrauterine Contraceptive Device that Migrated to the Bladder and Encrusted

Mesaneye Migre Olan ve Taşlaşmış İntrauterin Araç

Mehmet Gökhan Çulha, Bülent Mansuroğlu, Nejdet Karşıyakalı, Uğur Yücetaş, Ali Ferruh Akay

Intrauterine contraceptive devices (IUDs) are frequently used for birth control. Side-effects such as vaginal bleeding and localized pelvic pain are most common, and uterine perforation and migration of the adjacent organs are rare, but serious, complications. Herein we present the case of a 46-year-old woman who had a bladder stone because of an IUD that had migrated to the bladder and encrusted.

Keywords: Intrauterin contraceptive device, calculi, laser lithotripsy, migration

Intrauterin araçlar (İUA), doğum kontrol yöntemi olarak sık kullanılmaktadır. Vajinal kanama ve lokalize pelvik ağrı gibi yan etkiler sık görülmekle birlikte uterus perforasyonu, İUA'nın komşu organlara migrasyonu nadir görülen ve ciddi komplikasyonlar arasındadır. Bu olgumuzda İUA'nın mesaneye migre olması sonucu mesane taşı sap-tanan 46 yaşındaki kadın hasta sunulacaktır.

Anahtar Kelimeler: İntrauterin araç, kalkül, laser litotripsi, migrasyon.

Introduction

One of the most commonly selected contraceptive options is the intrauterine contraceptive device (IUD) because of its effectiveness of more than 99% in preventing pregnancy, low side-effect profile, and low cost (1). However, there are various complications in using IUDs, and these complications include migration into adjacent organs, pelvic abscesses, and uterine perforation (2). This is related to risk factors including postpartum uteruses, retroverted uteruses, and uteruses with small or irregular endometrial cavities along with the experience of the operator (3). Herein we present the case of a patient with an IUD that migrated to the bladder and that was diagnosed with bladder stone formation.

Case Report

Written informed consent was obtained from patient who participated. A 46-year-old female was admitted to the urology clinic with complaints of pollakuria and dysuria; these complaints were ongoing for three years. An IUD was implanted in the patient three years ago. She mentioned that her complaints had started after the IUD was implanted. For recurrent urinary system infection, this patient used cefuroxime axetil 500 mg and ciprofloxacin 500 mg. Apart from suprapubic tenderness, physical examination results was normal. Laboratory findings were normal apart from leucocyturia. On performing plain abdominal radiography, a calcified IUD was found in the pelvic area (Figure 1). The IUD, which was calcified and had migrated, was confirmed in the bladder on performing non-contrast computer tomography (Figure 2a, b). After this, cystoscopy was performed under spinal anesthesia. The stone located on the surface of the IUD was fragmented through laser lithotripsy (Sphinx, Lisa Laser, California, USA) (Figure 3a, b). The IUD was removed from the bladder via forceps after fragmentation. During control cystoscopy, no abnormal formation or fistula in the bladder was observed. At end of the operation, a Foley catheter was inserted. No bladder stone was detected when performing control plain abdominal radiography, and the patient was discharged with double antibiotics on the first post-operative day. No complaint was noted in the first post-operative month during follow-up outpatient visit.

Discussion

IUDs are considered to be one of the most effective and least expensive contraceptive methods (1). Bleeding, infection, ectopic pregnancy, and uterine perforation are associated complications with their usage. Migration into adjacent organs and uterine perforation are the major complications of IUDs. A migrated IUD may remain undetected for a long time (4). In terms of perforation, there are two proposed risk factors. First, the first 4 weeks of post-partum period may lead to an enlarged

Clinic of Urology, Health Sciences University Istanbul
Training and Research Hospital, Istanbul, Türkiye

Address for Correspondence

Yazışma Adresi:

Mehmet Gökhan Çulha

E-mail: gokhan_culha64@hotmail.com

Received/Geliş Tarihi: 13.08.2016

Accepted/Kabul Tarihi: 26.01.2017

© Copyright 2017 by Available online at
www.istanbulmedicaljournal.org

© Telif Hakkı 2017 Makale metnine
www.istanbultipdergisi.org web sayfasından
ulaşılabilir.

uterus with lochia and possible birth trauma; as the vulnerable uterus reverts to its normal size with a foreign object inside, this could lead to perforation (5). Second, it is believed that breastfeeding in-

creases the risk because it has been proposed that a small uterus due to low estrogen levels contributes to perforation (6).

The prevalence of IUDs migrating to the bladder can be as high as 14% (7). Calculus formation generally develops over time when an IUD migrates into the bladder. Calcium precipitation and calculus formation in a short time in the urinary system can be caused by foreign bodies such as IUDs, particularly those with metal parts, depending on the susceptibility of the host body to calculus formation, and this duration is thus variable and dependent on personal feature (8).

Plain radiography of the pelvis should be the first diagnostic procedure when the strings of IUD cannot be observed in a vaginal examination, is not detected in the endometrial cavity using ultrasonography (9). In this case, chronic inflammation of the uterine wall may lead to the migration of the IUD and result in calculus formation.

Depending on the location of the device and the potential involvement of adjacent organs, there are many ways to retrieve an IUCD (10). In the present case, we performed an endoscopic approach and fragmented the stone by laser lithotripsy. There was no complication on performing the procedure, and the patient's complaints resolved.

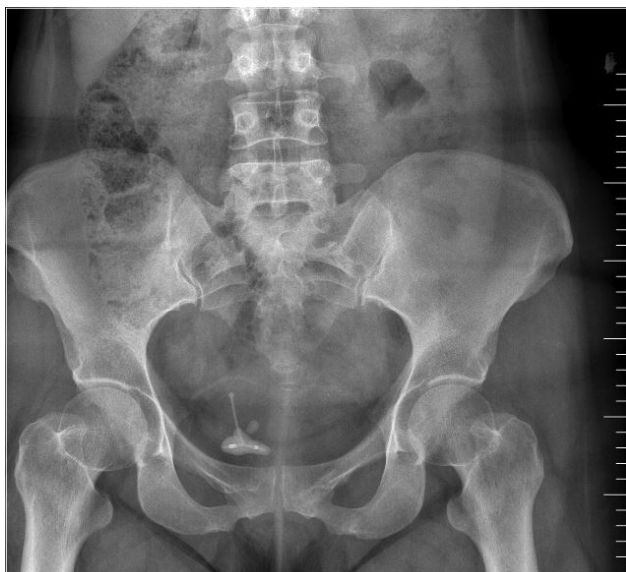

Figure 1. Encrusted intrauterine contraceptive device in the pelvic area. Plain abdominal radiography image.

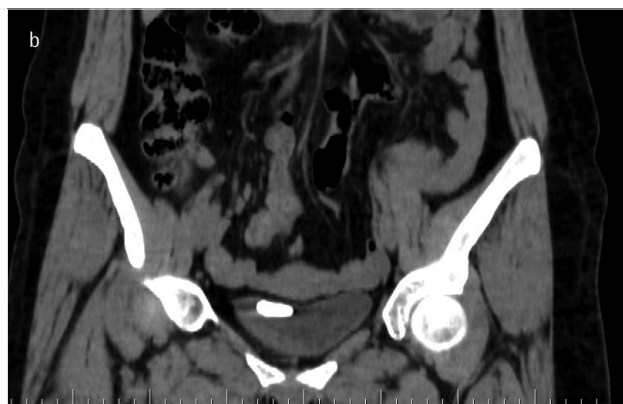
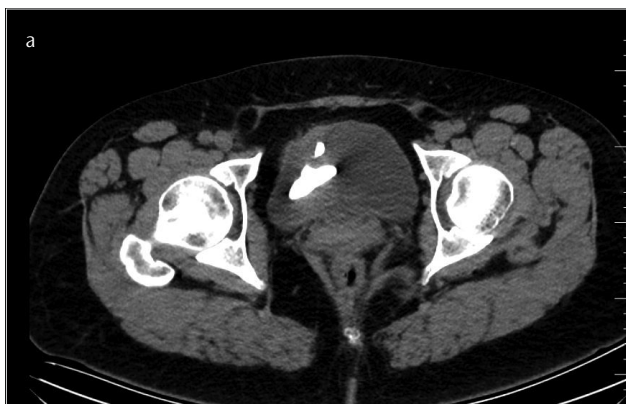
Figure 2. a, b. Image of the intrauterine contraceptive device that migrated to the bladder and the stoned device on performing computer tomography (a: axial section). Image of the intrauterine contraceptive device that migrated to bladder and the device on performing computer tomography (b: coronal section).

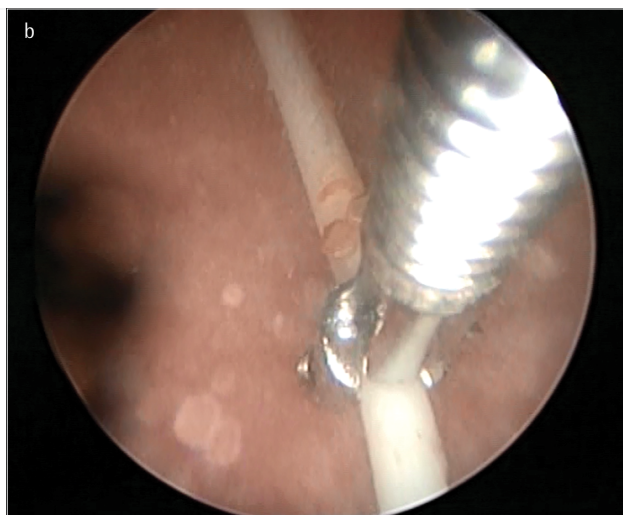
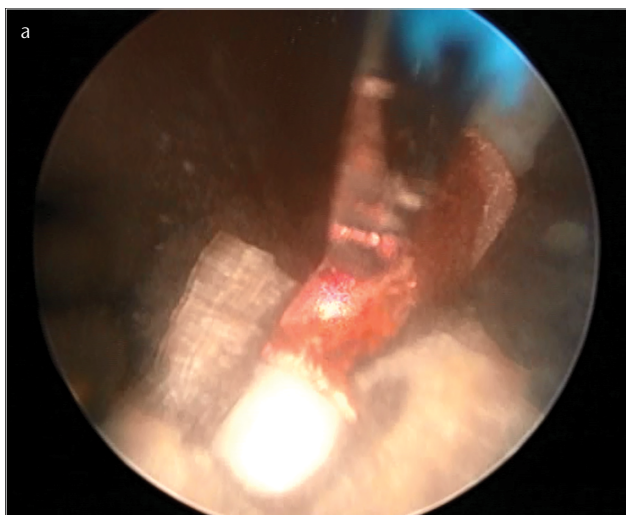


Figure 3. a, b. (a) Fragmentation of the stoned IUD by endoscopic laser lithotripsy. (b) Removal of the migrated IUD by forceps.

Conclusion

The migration of an IUD is a rare complication. In such cases, the IUD can be extirpated by laparotomy, laparoscopy, or endoscopy. Cystoscopy and laser lithotripsy are effective, reliable, and minimal invasive treatments for migrated IUDs.

Informed Consent: Verbal informed consent was obtained from patients' parents who participated in this study.

Peer-review: Externally peer-reviewed.

Author Contributions: Concept - A.F.A.; Design - N.K.; Supervision - U.Y.; Resources - M.G.Ç.; Materials - N.K.; Data Collection and/or Processing - M.G.Ç.; Analysis and/or Interpretation - B.M.; Literature Search - M.G.Ç.; Writing Manuscript - M.G.Ç., N.K.; Critical Review - U.Y., A.F.A.

Conflict of Interest: No conflict of interest was declared by the authors.

Financial Disclosure: The authors declared that this study has received no financial support.

Hasta Onamı: Sözlü hasta onamı bu çalışmaya katılan hastanın ailesinden ve hastadan alınmıştır.

Hakem Değerlendirmesi: Dış bağımsız.

Yazar Katkıları: Fikir - A.F.A.; Tasarım - N.K.; Denetleme - U.Y.; Kaynaklar - M.G.Ç.; Malzemeler - N.K.; Veri Toplanması ve/veya İşlemesi - M.G.Ç.; Analiz ve/veya Yorum - B.M.; Literatür Taraması - M.G.Ç.; Yazıyı Yazan - M.G.Ç., N.K.; Eleştirel İnceleme - U.Y., A.F.A.

Çıkar Çatışması: Yazarlar çıkar çatışması bildirmemişlerdir.

Finansal Destek: Yazarlar bu çalışma için finansal destek almadıklarını beyan etmişlerdir.

References

1. Heartwell SF, Schlesselman S. Risk of uterine perforation among users of intrauterine devices. *Obstet Gynecol* 1983; 61: 31-6.
2. El-Hefnawy AS, El-Nahas AR, Osman Y, Bazeed MA. Urinary complications of migrated intrauterine contraceptive device. *Int Urogynecol J Pelvic Floor Dysfunct* 2008; 19: 241-5. [\[CrossRef\]](#)
3. Kaislasuo J, Suhonen S, Gissler M, Lahteenmaki P, Heikinheimo O. Intrauterine contraception: incidence and factors associated with uterine perforation--a population-based study. *Hum Reprod* 2012; 27: 2658-63. [\[CrossRef\]](#)
4. Ko PC, Lin YH, Lo TS. Intrauterine contraceptive device migration to the lower urinary tract: report of 2 cases. *J Minim Invasive Gynecol* 2011; 18: 668-70. [\[CrossRef\]](#)
5. Kapp N, Curtis KM. Intrauterine device insertion during the postpartum period: a systematic review. *Contraception* 2009; 80: 327-36. [\[CrossRef\]](#)
6. Andersson K, Ryde-Blomqvist E, Lindell K, Odland V, Milsom I. Perforations with intrauterine devices. Report from a Swedish survey. *Contraception*. 1998; 57: 251-5. [\[CrossRef\]](#)
7. Kassab B, Audra P. The migrating intrauterine device. Case report and review of the literature. *Contraception, fertility, sexualite* (1992). 1999; 27: 696-700.
8. Dietrick DD, Issa MM, Kabalin JN, Bassett JB. Intravesical migration of intrauterine device. *J Urol* 1992; 147: 132-4. [\[CrossRef\]](#)
9. Ozcelik B, Serin IS, Basbug M, Aygen E, Ekmekcioglu O. Differential diagnosis of intra-uterine device migrating to bladder using radiographic image of calculus formation and review of literature. *Eur J Obstet Gynecol Reprod Biol* 2003; 108: 94-6. [\[CrossRef\]](#)
10. Subramanian V, Athanasias P, Datta S, Anjum A, Croucher C. Surgical options for the retrieval of a migrated intrauterine contraceptive device. *J Surg Case Rep* 2013; 2013.