



Appraisalment of Anterior Segment Changes caused by Vitrectomy without Internal Tamponade using Ultrasonic Biomicroscopy in Phakic Eyes

Erkan Ünsal, Kadir Eltutar, Mustafa Suat Alıkma, Osman Kızılay, Belma Karini

Abstract

Objective: Our study aimed to investigate morphological changes using ultrasonic biomicroscopy (UBM) in the anterior segment after phakic pars plana vitrectomy (PPV) without tamponade.

Methods: PPV surgery planned phakic patients were prospectively studied between October 2012 and March 2015. PPV patients who did not undergo cataract surgery and in whom intraocular tamponade was not used were included in the study. UBM measurements were taken a few days before and 10 days after the surgery. Through axial images of the anterior segment, the anterior chamber depth (ACD) and lens thickness (LT) were measured. Through the temporal quadrant over the radial cross-section images, the trabecular network-iris angle (TIA), ciliary body thickness (CBT), scleral thickness (ST), trabeculum-ciliary process's distance (T-CPD), iris-ciliary process's distance (I-CPD), and iris thickness (IT) were measured. Post- and preoperative values were statistically compared.

Results: A total of 21 patients (14 females and 7 males) were included. A total of 16 left eye and 5 right eye surgeries were performed. With respect to the preoperative measurement, postoperative mean values of ACD, CBT1, CBT2, CBT Max, T-CPD significantly decreased ($p=0.007$, $p=0.000$, $p=0.004$, $p=0.000$, $p=0.000$, respectively), and LT and TIA values were found to be increased (0.001, and 0.001, respectively).

Conclusion: PPV in phakic patients causes significant changes to the anterior segment parameters with ciliary body morphology.

Keywords: Ultrasound biomicroscopy, vitrectomy, phakic eye, anterior segment, ciliary body

Introduction

The first use of ultrasound biomicroscopy (UBM), which is an important method for monitoring and evaluating the anterior segment and the anterior chamber angle in ophthalmology, was made by Pavlin et al. (1) in the early 1990s. Sound energy is used in the high-frequency spectrum in UBM. With this spectrum, tissue penetration occurs to a depth of about 5 mm, which is more or less on the surface. UBM is a tool that enables the identification of not only anterior segment structures but also pathologies located in posterior segment structures such as the peripheral retina and ciliary body. It is an important imaging modality in the treatment of vitreoretinal diseases by cross-sectional imaging of the peripheral retina, pars plana, and vitreous base, which cannot be seen even via indirect ophthalmoscopy performed using a scleral buckling method.

The most important advantage of UBM compared with anterior segment optical coherence tomography is that posterior chamber structures such as the ciliary body, lens zonules, and anterior choroid can also be displayed without dilating the pupils (2).

In many vitreoretinal diseases, pars plana vitrectomy (PPV) is applied as the standard surgical approach. Many complications related to PPV may be encountered postoperatively. Some of these complications are related to the anterior segment.

The aim of this study was to investigate by UBM postoperative changes in the morphology of the anterior segment in phakic patients in whom tamponade was not used during PPV.

Methods

Between March 2012 and October 2015, phakic patients for whom PPV was planned were included in the study prospectively. Patients on whom cataract surgery was performed along with PPV and/or gas or silicone oil was used as intraocular tamponade were excluded from the study, and 21 eyes of 21 patients were statistically included in the evaluation.

The study was performed in accordance with the Helsinki Declaration. All patients who were included in the study were given information regarding the intervention and written informed consent was received. Approval of the local ethics committee was obtained for the execution of the work.

Clinic of Eye, Istanbul Training and Research Hospital,
Istanbul, Türkiye

Address for Correspondence:
Erkan Ünsal
E-mail: erkanunsal@gmail.com

Received:
12.10.2015

Accepted:
29.12.2015

© Copyright 2016 by Available online at
www.istanbulmedicaljournal.org

Preoperatively, all patients underwent a complete ophthalmological examination. A detailed medical history of the patients was taken, and their age, sex, systemic disease, and drugs used, if any, were recorded. For identifying the refraction of the patients, best corrected distance visual acuity was determined according to the Snellen scale. Their intraocular pressures (IOPs) were measured by Goldmann applanation tonometry. The anterior chamber angles were measured with a Goldmann three-mirror lens.

Prior to surgery, patients with a history of uveitis or glaucoma, patients using topical or systemic medications that may affect the pupil or accommodation, patients who previously underwent intraocular surgery or anterior segment laser surgery, and patients in whom scleral buckling material was used with PPV were excluded from the study. After surgery, patients with IOPs of less than 10 mmHg and higher than 22 mmHg were excluded from the study.

About a week before surgery, 1.25 mg/0.05 mL intravitreal bevacizumab (Avastin; Genentech, Inc., South San Francisco, CA, USA) was injected into nine patients due to intravitreal hemorrhage (VH) as a result of diabetic retinopathy (DR), two patients because of chronic significant cystoid macular edema (CSCME), three patients due to VH secondary to branch retinal vein occlusion (VH-BRVO), and one patient due to VH secondary to central retinal vein occlusion (VH-CRVO), for whom PPV was planned.

All patients were operated on by a single surgeon using the same surgical protocol. PPV was performed accompanied by a BIOM non-contact wide-angle imaging system (Oculus, Germany). The presence of a posterior hyaloid was checked with the help of triamcinolone acetonide in all cases and, if not detached, it was cleared by applying a vacuum with the tip of the vitrectomy probe. Peripheral vitrectomy was performed using scleral buckling. Pan-retinal photocoagulation was applied to all patients with VH due to DR. Laser photocoagulation was performed on the quadrant with vein obstruction in VH-BRVO patients. When necessary, scleral entry sites were sutured. After surgery, prednisolone acetate and lomefloxacin drops every 2 h were prescribed for all patients.

As repeatability with different observers is variable, UBM examinations were performed by one observer using the same device (Sonomed VuMAX II®) and the 35 MHz probe of this device before surgery (24–48 h) and at least 10 days after surgery (10–20 days) (13±4 days). All UBM examinations were performed under a protocol by which a standard environment and conditions were met. In order to ensure the natural dilatation of the pupil, images were taken from patients who were looking at a red target hanging from the ceiling, to prevent accommodative effort in a dim room, and in the supine position. Thus, an attempt was made to bring under control environmental factors that could affect the anterior segment and the angle anatomy.

Topical proparacaine HCl 0.5% (Alcaine®, Alcon®) was dropped in patients' eyes and, after 10–15 seconds, a soft silicone eye cup of an appropriate diameter (18, 20, or 22 mm) was placed between the conjunctival fornices of the upper and lower lids. Measurements of each patient were made using the same eye cup before and after the operation. In order to avoid corneal contact, the focal distance of the probe was set to 12 mm and, after the eye cup was filled with a sufficient amount of sterile saline solution to achieve immersion, the scan was started.

Axial images of the anterior chamber were taken first, and later radial cross-sectional images of the angle were taken from the temporal quadrant. In order to obtain ideal images and then be consistent with the measurements we would make later, special attention was paid to the images being balanced in the axial scans of the anterior segment (aligned and symmetrical about the theoretical central horizontal line) and to the order of vertical alignment (cornea, lens, and anterior and posterior capsule balanced around the theoretical central vertical line). While taking the radial cross-sectional images of the angle, the direction of the markers was set perpendicular to the limbal region in the scanned quadrant and special attention was paid to the selection of the images that gave the best reflectivity of the iris. In order for the localization of the scleral spur (SS) to be accurate and easy, attention was paid to the apparent reflectance of the interface between the sclera and the ciliary body and to good images of the ciliary body and iris (3). Attention was paid to the reflection of the interface between the ciliary body and the sclera being apparent and to the quality of the images of the iris and ciliary body in order for accurate and easy localization of the SS.

By means of the axial images of the anterior segment, the central axial anterior chamber depth (ACD) and lens thickness (LT) were measured using the scales in the software of the device using the method that Palvin et al. (4, 5) suggested previously.

1. The axial ACD measurement was determined by measuring the distance between the central corneal rear surface and the peaks of the lens anterior capsule in the pupillary midline (Figure 1).

2. To determine the LT, the distance between the anterior and posterior lens capsules was measured (Figure 1a).

Then, from the radial cross-sectional images of the angle in the temporal quadrant:

3. The trabecular meshwork–iris angle (TIA) was determined from the peak at the edge of the iris and the trabecular meshwork, with one of the arms 500 µm from the SS and the other measured perpendicularly to the surface of the iris (Figure 1b).

4. The ciliary body thickness (CBT) was measured in four regions:
a) at a distance of 1 mm (CBT 1) from the SS (Figure 1c);
b) at a distance of 2 mm (CBT 2) from the SS (Figure 1d);
c) at a distance of 3 mm (CBT 3) from the SS (Figure 1c); and
d) the thickest part of the ciliary body (CBT max) was measured (Figure 1d).

5. Trabecular meshwork–ciliary process distance (T-CPD): the distance to the front ciliary process was measured at 500 µm from the front of the SS along the corneal endothelium, vertically through the iris (Figure 1e).

6. Iris–ciliary process distance (I-CPD): the distance from the iris pigmented epithelium to the ciliary processes was measured (Figure 1f).

7. Scleral thickness (ST): the distance from the SS to the episcleral surface was measured perpendicularly (Figure 1g).

8. Iris thickness (IT) was measured in three zones:
a) IT-1: through a line on the T-CPD (Figure 1h);
b) IT-2: at a distance of 2 mm from the iris root to the centre (Figure 1h); and

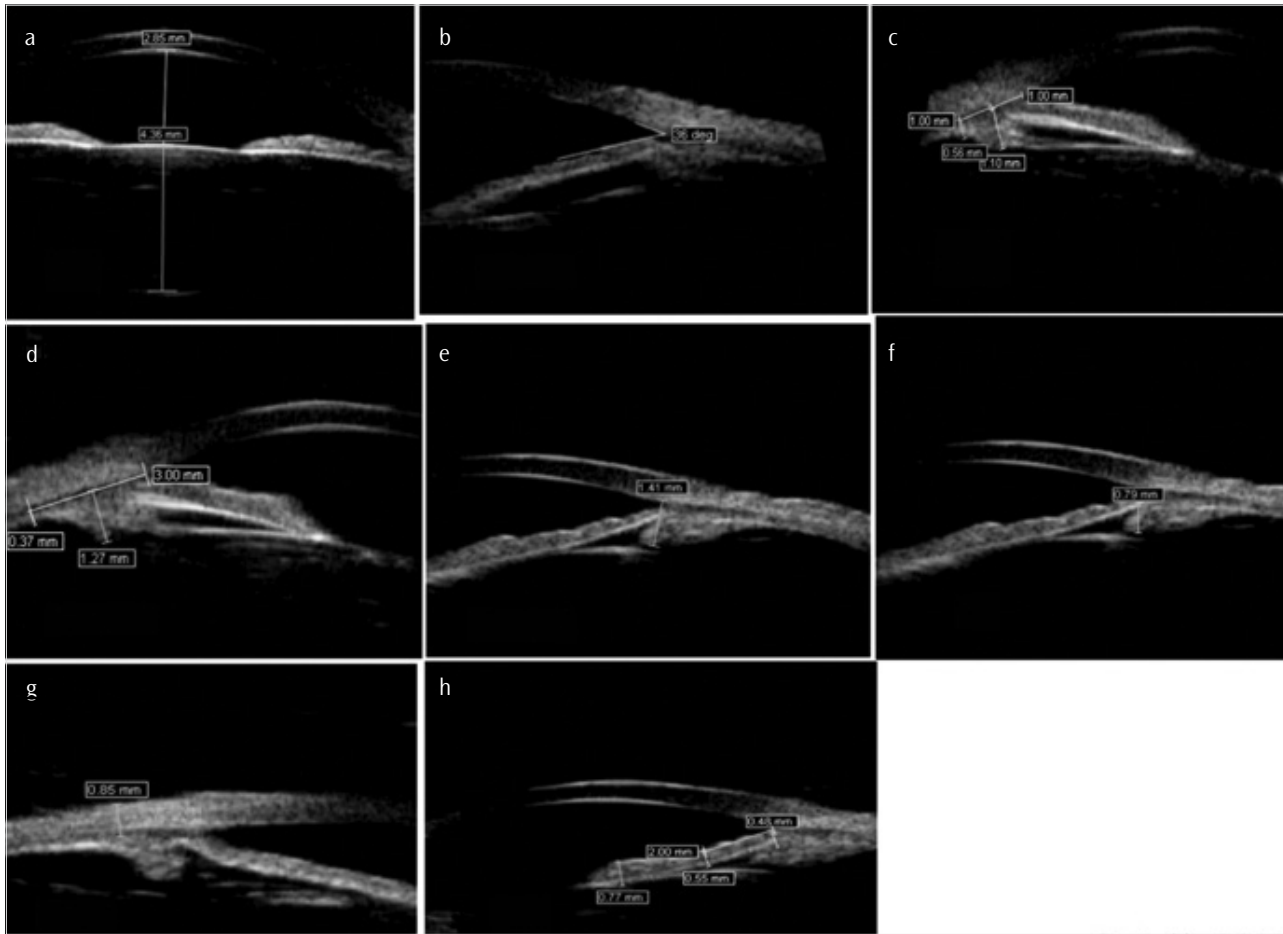


Figure 1. a-h. UBM images of the axial anterior segment and radial cross-sectional image of the temporal quadrant. (a) UBM image of the anterior chamber depth and lens thickness, (b) UBM image of the trabecular meshwork–iris angle, (c) UBM image of ciliary body thicknesses 1–3, (d) UBM image of ciliary body thickness 2 and the thickest part of the ciliary body, (e) UBM image of the trabecular meshwork–ciliary process distance, (f) UBM image of the iris–ciliary process distance, (g) UBM image of the scleral thickness, and (h) iris thicknesses 1, 2, and 3
UBM: ultrasonic biomicroscopy

c) IT-3: pupils were measured from the thick area next to the edge (Figure 1h).

At least 10 days (10–15 days) after surgery, patients’ UBM examinations and the measurements given above in detail were repeated. Values obtained before and after surgery were compared.

Statistical analysis

When assessing the findings obtained in this study, the Statistical Package for the Social Sciences 15.00 for Windows software (SPSS, Inc.; Chicago, IL, USA) was used for statistical analysis.

Values obtained before and after the operation were assessed using a paired-samples t-test. Results were evaluated at a confidence interval of 95% and a significance level of $p < 0.05$.

Results

With an average age of 60.23 ± 12.51 (40–74) years, a total of 21 patients (14 women and seven men), on whom cataract surgery was not performed and intraocular tamponade was not used, were included in this study, in which 16 left eyes and five right eyes were examined (Table 1).

Nine of the patients were operated on with a diagnosis of VH due to DR, two with a diagnosis of DR-related CSCME, three with a di-

agnosis of VH-BRVO, one with a diagnosis of VH-CRVO, and six with epiretinal membrane (ERM) (Table 1).

After surgery, the average values of ACD, CBT 1, CBT 2, CBT Max, and T-CPD decreased statistically significantly (with respective values of $p=0.007$, $p=0.000$, $p=0.004$, $p=0.000$, and $p=0.000$) and the values of LT and TIA were found to have increased (with respective values of $p=0.001$ and $p=0.001$) in comparison with the preoperative values (Table 2).

There were no statistically significant changes ($p > 0.05$) in the other examined parameters before and after surgery (Table 2).

Discussion

In this study, in phakic patients who underwent PPV without tamponade being used, about 10 days after the operation significant decreases in the average values of ACD, CBT 1, CBT 2, CBT Max, and T-CPD and significant increases in the values of TIA and LT were found.

The repeatability, accuracy, and precision of the measurements in UBM were investigated (6-10). Gaining enough experience to take an ideal image in UBM requires time. There are various publications available that indicate that the reproducibility of the measurements made with this technology is favorable with the same

Table 1. Demographic and clinical characteristics of the patients

Number of patients (eyes)	21
Gender (M/F)	7/14
Average age (years)±SD (min–max)	60.23±12.51 (40–74)
Eye (right/left)	5/16
DR-VH/DR-CSCME/BRVO-VH/CRVO-VH/IERM	9/2/3/1/6

SD: standard deviation; DR-VH: intravitreal hemorrhage secondary to diabetic retinopathy; DR-CSCME: chronic significant cystoid macular edema due to diabetic retinopathy; VH-BRVO: intravitreal hemorrhage secondary to branch retinal vein occlusion; VH-CRVO: intravitreal hemorrhage secondary to central retinal vein occlusion; IERM: idiopathic epiretinal membrane

Table 2. Comparison of preoperative and postoperative anterior chamber and angle parameters in the temporal quadrant

	Pre	Post	p
ACD (mm)	2.499±0.35	2.416±0.30	0.007
LT (mm)	3.957±0.84	4.221±0.79	0.001
TIA (°)	26.904±4.08	29.952±3.16	0.001
CBT 1	1.066±0.10	0.909±0.21	0.000
CBT 2	0.686±0.20	0.537±0.11	0.004
CBT 3	0.405±0.18	0.353±0.06	0.250
CBT max	1.211±0.78	1.083±0.10	0.000
ST	0.959±0.11	0.946±0.4	0.586
T-CPD	1.560±0.26	1.311±0.22	0.000
I-CPD	0.971±0.14	0.868±0.18	0.083
IT-1	0.490±0.04	0.495±0.08	0.749
IT-2	0.452±0.03	0.457±0.03	0.689
IT-3	0.586±0.05	0.589±0.04	0.731

ACD: anterior chamber depth; LT: lens thickness; TIA: trabecular meshwork–iris angle; CBT 1, 2, and 3: ciliary body thicknesses at 1, 2, and 3 mm from the sclera spur; CBT max: maximum thickness of the ciliary body; T-CPD: trabecular meshwork–ciliary process distance; I-CPD: iris–ciliary process distance; IT-1, 2, and 3: iris thicknesses 1, 2, and 3

observer and weak between different observers (6–11). The main reason for this variability is the quality of the image obtained. In addition, variability in the analysis of the measurements should not be ignored. The main causes underlying this variability are selecting the image frame to be measured and differences in identifying the location of the SS. Therefore, comparison of measurements made before and after any procedure should be made by the same observer. Therefore, preoperative and postoperative UBM measurements and their comparison were performed by a single observer.

Ultrasound biomicroscopy evaluation of the anterior chamber angle may also be affected by physiological variables besides image acquisition quality and differences in analysis. Because the room illumination level, fixation, and accommodative effort are factors that affect the anterior segment anatomy, these factors should remain constant, particularly while quantitative measures are made. We also made our measurements under a protocol that provides a standard environment and conditions.

After posterior segment surgery such as scleral buckling, changes in the anterior segment have been described in the first weeks

(12–16). However, information about the effects of vitrectomy on the anterior segment morphology is limited. If the effects of vitrectomy on the anterior segment morphology can be detected, complications can be prevented in predisposed eyes.

Calik et al. (17) evaluated the anterior segment structure in 22 cases that used internal silicone oil tamponade and 22 cases that underwent PPV without tamponade with a Pentacam Scheimpflug camera before the operation and a week and a month after the operation.

Although the average ACD in the group in which tamponade was not used decreased from 2.99 mm before the operation to 2.40 mm in the first postoperative week and 2.64 mm in the first month, this change was not statistically significant. In our study, the average ACD decreased from 2.49 mm before the operation to an average of 2.41 mm after the operation and this decrease was found to be statistically significant. In the same study (17), although the average TIA increased from 33.6° a week before the operation to 35.0° a week after the operation and 34.5° a month later, this difference was not found to be statistically significant in the group where tamponade was not used. In our study, the TIA increased from 26.9° to 29.9° and this increase was found to be statistically significant. The increase in the TIA together with the decrease in the ACD may be due to the backward orientation of the iris root.

Nevdorfer et al. (18), in a study in which they evaluated changes in the anterior segment of 28 cases by using high-frequency UBM before PPV and 1–2 days after PPV, in a subgroup of 13 cases that consisted of phakic and pseudophakic patients where internal tamponade was not used the ACD decreased from 3.34 mm preoperatively to 3.29 mm after the operation, yet this decrease was not found to be statistically significant. In the same subgroup, although the LT, which was 4.17 mm before the operation, increased to 4.22 mm after the operation, this increase was not statistically significant. In this subgroup of 13 cases in which the numbers of phakic and pseudophakic patients were not certain, if there had been more patients and phakic patients, a statistically significant decrease in ACD and an increase in LT would probably have been detected. In our study, which entirely consisted of phakic patients, a significant decrease in ACD and a significant increase in LT were detected.

Nevdorfer et al. (18) did not establish a correlation between an increase in IOP and ACD in the same study. In our study, this correlation could not be assessed because patients with an IOP of lower than 10 mmHg and higher than 22 mmHg were excluded from the study.

Kim and Yu (19), in a study in which they measured the CBT of patients with diabetic macular edema (DME) by UBM, evaluated a group of 26 patients with diffuse DME and a group of 23 patients with non-diabetic ERM before and after PPV. They also formed a control group that consisted of normal healthy cases. In the DME group, they found that the average CBT was statistically significantly larger before the operation than in both the normal control group and the idiopathic ERM group. After the operation, although a significant decrease was detected in the average CBT of the DME group, they observed no change in the ERM group. It was stated that an increase had occurred in the CBT of the patients

with DME as a result of edema, and a significant decrease in CBT was achieved by vitrectomy in the DME group. In our study, a significant proportion of the patients had DR-related complications and at the end of the operation significant decreases were found in the average values of CBT 1, CBT 2, and CBT Max. In our study, in contrast to that conducted by Kim and Yu (19), an anti-vascular endothelial growth factor (VEGF) injection was administered to 15 patients about a week before the operation. Intravitreal injections of anti-VEGF agents are known to decrease DME (20-22). Similarly, a decrease in CBT can also be expected. In addition, it was shown that the average VEGF level in the vitreous fell after PPV (23).

In our study, intraoperative laser photocoagulation was applied to 15 patients. Tatlıpınar et al. (24), in a study of 28 eyes of 18 type 2 diabetes patients in which they evaluated the calibration measurements of retinal veins before and after laser treatment in eyes with proliferative DR on which panretinal photocoagulation was performed, after laser photocoagulation found a statistically significant decrease in the diameters of retinal arteries and veins. This decrease in vessel diameters may indirectly indicate a decrease in retinal tissue mass on laser photocoagulation. There are studies that indicate that panretinal laser photocoagulation causes a reduction in retinal thickness (20, 25, 26). The reason for the decrease in CBT may be due to a combined effect in addition to anti-VEGF injection, vitrectomy, and laser photocoagulation.

Marigo et al. (27) reported that in a working group that consisted of 20 patients who underwent vitrectomy, there was no statistically significant change in the anterior segment morphology measurements they made by UBM before the operation and one month after the operation. In contrast to our study, this study included both phakic and pseudophakic patients. Our study included only phakic patients. Furthermore, it was not specified in this study whether or not an intravitreal anti-VEGF injection was performed before the operation. In our study, an anti-VEGF injection was applied to 15 patients.

Among the inadequacies of our study were that the patients were not re-evaluated by UBM in later periods in addition to the early postoperative period (10 days), a control group was not formed, the working group consisted of cases with different diagnoses, and UBM measurements were made in the axial and temporal quadrants and not in other quadrants.

Conclusion

Pars plana vitrectomy has a significant effect on the morphology of the anterior segment. In order to better understand the effects of PPV on the anterior segment, research should be carried out with large series of patients having the same diagnosis using more advanced devices.

Ethics Committee Approval: Ethics committee approval was received for this study.

Informed Consent: Written informed consent was obtained from patients who participated in this study.

Peer-review: Externally peer-reviewed.

Author Contributions: Concept - E.Ü.; Design - E.Ü.; Supervision - E.Ü., K.E.; Funding - E.Ü.; Materials - E.U.; Data Collection and/or Processing

- E.Ü., K.E., M.S.A., O.K., B.K.; Analysis and/or Interpretation - E.Ü., K.E.; Literature Review - E.Ü.; Writing - E.Ü.; Critical Review - E.Ü.; Other - E.Ü.

Conflict of Interest: No conflict of interest was declared by the authors.

Financial Disclosure: The authors declared that this study has received no financial support.

References

- Pavlin CJ, Sherar MD, Foster FS. Subsurface ultrasound microscopic imaging of the intact eye. *Ophthalmology* 1990; 97: 244-50. [CrossRef]
- Friedman DS, He M. Anterior chamber angle assesment techniques. *Surv Ophthalmol* 2008; 53: 250-73. [CrossRef]
- Ishikawa H, Liebmann JM, Ritch R. Quantitative assessment of the anterior segment using ultrasound biomicroscopy. *Curr Opin Ophthalmol* 2000; 11: 133-9. [CrossRef]
- Pavlin CJ, Harasiewicz K, Sherar MD, Foster FS. Clinical use of ultrasound biomicroscopy. *Ophthalmology* 1991; 98: 287-95. [CrossRef]
- Pavlin CJ, Harasiewicz K, Foster FS. Ultrasound biomicroscopy of anterior segment structures in normal and glaucomatous eyes. *Am J Ophthalmol* 1992; 113: 381-9. [CrossRef]
- Tello C, Liebmann J, Potash SD. Measurement of ultrasound biomicroscopy images: intraobserver and interobserver reliability. *Invest Ophthalmol Vis Sci* 1994; 35: 3549-52.
- Urbak SF, Pedersen JK, Thorsen TT. Ultrasound biomicroscopy. II. Intraobserver and interobserver reproducibility of measurements. *Acta Ophthalmol Scand* 1998; 76: 546-9. [CrossRef]
- Urbak SF. Ultrasound biomicroscopy. I. Precision of measurements. *Acta Ophthalmol Scand* 1998; 76: 447-55. [CrossRef]
- Urbak SF. Ultrasound biomicroscopy III. Accuracy and agreement of the measurements. *Acta Ophthalmol Scand* 1999; 77: 293-7. [CrossRef]
- Marchini G, Pagliaruso A, Toscano A, Tosi R, Brunelli C, Bonomi L. Ultrasound biomicroscopic and conventional ultrasonographic study of ocular dimensions in primary angle-closure glaucoma. *Ophthalmology* 1998; 105: 2091-8. [CrossRef]
- Spaeth GL, Azuara-Blanco A, Araujo SV, Augsburger JJ. Intraobserver and interobserver agreement in evaluating the anterior chamber angle configuration by ultrasound biomicroscopy. *J Glaucoma* 1997; 6: 13-7. [CrossRef]
- Pavlin CJ, Rutnin SS, Devenyi R, Wand M, Foster FS. Supraciliary effusions and ciliary body thickening after scleral buckling procedures. *Ophthalmology* 1997; 104: 433-8. [CrossRef]
- Maruyama Y, Yuuki T, Kimura Y, Kishi S, Shimizu K. Ciliary detachment after retinal detachment surgery. *Retina* 1997; 17: 7-11. [CrossRef]
- Yoshida S, Sasoh M, Arima M, Uji Y. Ultrasound biomicroscopic view of detachment of the ciliary epithelium in retinal detachment with atopic dermatitis. *Ophthalmology* 1997; 104: 283-7. [CrossRef]
- Kawahara S, Nagai Y, Kawakami E, Ida RY, Takeuchi M, Uyama M. Ciliochoroidal Detachment Following Scleral Buckling Surgery for Rhegmatogenous Retinal Detachment. *Jpn J Ophthalmol* 2000; 44: 692-3. [CrossRef]
- Coleman DJ. Evaluation of ciliary body detachment in hypotony. *Retina* 1995; 15: 312-8. [CrossRef]
- Calik B, Öztürk M, Serdarogullari H, Elçioglu M. Evaluation of anterior segment parameters using pentacam in silicone oil-injected patients after pars plana vitrectomy. *Indian J Ophthalmol* 2013; 61: 621-5. [CrossRef]
- Neudorfer M, Oren N, Barak A. High-frequency ultrasound biomicroscopy of the anterior segment morphometry before and immediately after pars plana vitrectomy. *Eur J Ophthalmol* 2011; 21: 73-8. [CrossRef]
- Kim C, Yu HG. Changes in ciliary body thickness in patients with diabetic macular edema after vitrectomy. *Retina* 2012; 32: 1316-23. [CrossRef]
- Liegl R, Langer J, Seidensticker F, Reznicek L, Haritoglou C, Ulbig MW, et al. Comparative evaluation of combined navigated laser photocoagulation and intravitreal ranibizumab in the treatment of diabetic macular edema. *PLoS One* 2014; 26: e113981. [CrossRef]

21. Selen F, Demirel S, Batođlu F, Özmert E. Intravitreal ranibizumab enjeksiyonu uygulanan diabetik maküla ödemli olgularda görme keskinliğini etkileyen faktörler. *Retina-Vitreus* 2013; 21: 269-73.
22. Kobat SG, Turgut B, Çeliker Ü, Demir T. Refrakter diabetik maküler ödem tedavisinde intravitreal ranibizumab enjeksiyonu. *Retina-Vitreus* 2014; 22: 257-64.
23. Lee SS, Ghosn C, Yu Z, Zacharias LC, Kao H, Lanni C, et al. Vitreous VEGF clearance is increased after vitrectomy. *Invest Ophthalmol Vis Sci* 2010; 51: 2135-8. [\[CrossRef\]](#)
24. Tatlıpınar S, Yıldırım C, Yaylalı V, Özden S. Diabetik retinopatide pan-retinal fotokoagülasyon sonrası retina damar çapı değişiklikleri. *MN-Oftalmoloji Dergisi* 2004; 11: 235-7.
25. Pei-Pei W, Shi-Zhou H, Zhen T, Lin L, Ying L, Jiexiong O, et al. Randomised clinical trial evaluating best-corrected visual acuity and central macular thickness after 532-nm subthreshold laser grid photocoagulation treatment in diabetic macular oedema. *Eye (Lond)* 2015; 29: 313-21. [\[CrossRef\]](#)
26. Park YG, Kim EY, Roh YJ. Laser-based strategies to treat diabetic macular edema: history and new promising therapies. *J Ophthalmol* 2014; 2014: 769213. [\[CrossRef\]](#)
27. Marigo FA, Zisman M, Nehemy MB, Marigo PVB. Ultrasound biomicroscopy in the comparison of the anterior segment morphometry before and after pars plana vitrectomy. *Arq Bras Oftalmol* 2006; 69: 919-22.