



Transoral Laser Microsurgery for Glottic Cancers - Complications and Importance of the Anterior Commissure Involvement

Glottik Kanserler için Transoral Lazer Mikrocerrahi Yöntemi - Komplikasyonlar ve Ön Komissür Tutulumunun Önemi

Deniz Tuna Edizer¹, Harun Cansız²

Abstract / Özet

Objective: Transoral laser microsurgery (TLM) for laryngeal cancer has some complications that are being reported more frequently as its use has become widespread. Anterior commissure (A-com) involvement of the laryngeal cancer carries some disadvantages such as inadequate exposure in some cases and high recurrence rate following surgery. We evaluated TLM of glottic cancers in terms of complications and A-com involvement.

Methods: Sixty-two patients with biopsy proven, previously untreated T1, T2 and T3 glottic cancer were enrolled into the study. Mean follow-up period was 35.3 months. All cases were treated with diode laser. A-com involvement and its impact on local recurrence, utility of second look operations and complications of TLM were investigated.

Results: A-com involvement was seen in 13 patients (22%). Local recurrence was more frequent in patients with A-com involvement (15%) compared to those without A-com involvement (6%), with no statistical significance ($p>0.05$). The most frequent complication of TLM was granulation tissue formation. The ratio of second-look operations was higher for cases with A-com involvement (61%), than those without A-com involvement (11%).

Conclusion: TLM for glottic cancers involving A-com carries a higher local recurrence rate in this series. Second look operations have the advantages of detecting and treating recurrences earlier.

Key Words: Transoral laser microsurgery, glottic cancer, anterior commissure, second look operation, complication

Amaç: Transoral lazer mikrocerrahi (TLM) yönteminin laringeal kanser için kullanımı yaygınlaştıkça komplikasyonları daha fazla bildirilmeye başlanmıştır. Laringeal kanserde, ön komissür (Ön-kom) tutulumunun yetersiz ekspozisyon ve cerrahi sonrası yüksek nüks oranı gibi bazı dezavantajları vardır. Çalışmamızda glottik kanserler için kullanılan TLM komplikasyon ve Ön-kom tutulumu açısından değerlendirilmiştir.

Yöntemler: Biopsi ile ispatlanmış ve daha önce tedavi edilmemiş T1, T2 ve T3 glottik kanseri olan 62 hasta çalışmaya dahil edildi. Ortalama takip süresi 35.3 ay idi. Tüm olgular diod lazer ile tedavi edildi. Ön-kom tutulumu ve Ön-kom tutulumunun lokal nüks üzerine etkisi, ikinci bakış cerrahisinin yararı ve TLM'nin komplikasyonları incelendi.

Bulgular: Ön-kom tutulumu 13 hastada (%22) izlendi. Lokal nüks, Ön-kom tutulumu olan hastalarda (%15) olmayanlara göre (%6) daha fazla bulunmasına rağmen, istatistiksel anlamlılık tespit edilmedi ($p>0.05$). En sık görülen komplikasyon granülasyon dokusu oluşumu idi. İkinci bakış cerrahisinin oranı Ön-kom tutulumu olanlarda %61, olmayanlarda %11 idi.

Sonuç: Serimizde, Ön-kom tutulumu olan glottik kanserler için uygulanan TLM daha fazla lokal nüks oranına sahiptir. İkinci bakış cerrahisi, nüksleri daha erken tespit ve tedavi etme avantajına sahiptir.

Anahtar Kelimeler: Transoral lazer mikrocerrahisi, glottik kanser, ön komissür, ikinci bakış cerrahisi, komplikasyon

Introduction

Transoral laser microsurgery (TLM) is a surgical option which is considered as effective as open surgical techniques, especially for early laryngeal cancers. Piecemeal removal of the tumor and secondary intention healing are the two features that distinguish TLM from open surgery (1). Piecemeal removal under the operating microscope allows for continuing assessment of the tumor depth, which may avoid unnecessary removal of healthy tissue. Since TLM does not involve reconstruction, granulation tissue forms during the healing process and remucosalization follows. These features help prevent covering of the residual tumor and make identification of the recurrence earlier and easier (2). Low recurrence and high survival rates make TLM a useful surgical option for laryngeal cancers (3). Even for advanced laryngeal cancers, the use of TLM with or without radiotherapy is considered as a valid treatment option (4).

Avoidance of tracheotomy and shorter duration of hospital stay, together with equivalent surgical results to open surgery, contribute to the widespread use of laser treatment for laryngeal cancers. This widespread use undoubtedly contributed to the perception of some complications. One of the most important complications is the airway compromise which is rarely encountered (1). On the other hand, bleeding was reported to be one of the most common complications. The incidence of complications increases with tumor size and associated resections (5).

Anterior commissure (A-com) involvement in laryngeal carcinoma was reported to be associated with increased local recurrence (6,7). The role of A-com in the spread of cancer (a barrier or a path for cancer) is controversial. On the other hand, resection of the region of A-com may lead to scarring, granuloma and web formation. Therefore, A-com involvement demands careful examination and follow-up, and sometimes necessitates second look operations, which may detect recurrent or residual disease earlier (8).

¹Department of Otolaryngology, Bayrampasa State Hospital, Istanbul, Türkiye

²Department of Otolaryngology, Cerrahpaşa School of Medicine, Istanbul University, Istanbul, Türkiye

Address for Correspondence

Yazışma Adresi:

Deniz Tuna Edizer, Department of Otolaryngology, Bayrampasa State Hospital, Istanbul, Türkiye
Phone: +90 212 560 59 16
E-mail: deniztunaedizer@yahoo.com

Received Date/Geliş Tarihi:
22.05.2012

Accepted Date/Kabul Tarihi:
12.08.2012

© Copyright 2013 by Available online at
www.istanbultipdergisi.org

© Telif Hakkı 2013 Makale metnine
www.istanbultipdergisi.org web sayfasından
ulaşılabilir.

In this study, we evaluated the effects of TLM for glottic carcinoma in terms of A-com involvement and complications.

Methods

Sixty-two patients with untreated but biopsy proven T1, T2 and T3 glottic carcinoma were enrolled in this study from 2005 to 2008. All patients had the diagnosis of squamous cell carcinoma and none had received radiotherapy to the head and neck region for any reason. Endoscopy of the oral cavity, oropharynx, larynx and esophagus was performed to accurately stage the disease before definitive therapy. The patients were staged according to the 2002 criteria of American Joint Committee on Cancer (AJCC). Cervical lymph node involvement was assessed by both palpation and computed tomography.

All patients were intubated transorally before surgery. Following adequate exposure of the larynx with the help of adjustable laryngoscopes, the diode laser was utilized for tumor removal. The modality was a continuous wave radiation delivered to a flexible optical fiber. The output power of the laser was variable, adjusted at 6-12 W, and removal of the tumor was performed until healthy looking tissue was evident. The cartilagenous framework of the larynx was always left intact. Following removal of the tumor, biopsy of the healthy looking mucosa was carried out to rule out margin positivity. Elective tracheostomy was not performed during surgery, but the patients were observed closely after extubation for airway control. Neck dissection was performed only in patients with clinically and/or radiologically positive nodes. No elective neck dissection was performed. Adjuvant radiotherapy was reserved for cases of incomplete resection of the primary tumor (positive margin) and for those with local or regional recurrences who had rejected surgical intervention. Patients were followed-up for approximately 3 years with intervals of 3-5 months. For those patients with suspected local recurrence, a second look operation was performed to rule out malignancy.

Complications were recorded intraoperatively and postoperatively (early-late). Early postoperative complication was defined as those occurring in the first few days (inpatient period) following surgery, whereas late complication was defined as occurring later.

Chi-square statistical method was used for statistical analysis (SPSS version 17). A *p* value of less than 0.05 was considered statistically significant.

Results

Patients were followed for a mean period of 35,3 months (range, 24 months to 48 months). Four patients were lost in the follow-up period. The reasons for exclusion were death in 3 patients (due to lung and prostate cancer in 2 patients and cerebrovascular accident in 1 patient) and loss of contact in another patient. Hence, the study included 58 patients. The mean age of the patients was 60.43 years (range, 42 to 78). The case study included 7 females and 51 males. Fifty-one patients (88%) were active smokers. According to the 2002 American Joint Committee on Cancer (AJCC), the tumors were classified as T1a (30 patients), T1b (7 patients), T2 (15 patients) and T3 (6 patients).

Limited vocal fold mobility was present in 3 patients at the time of diagnosis, and these patients were staged as T2, whereas vocal

fold fixation was present in 3 patients, who were staged as T3. In those patients with T3 primary tumor, the extent of resection was deeper, and in 1 of these patients the laryngeal framework (thyroid cartilage) was exposed.

Margin positivity was present in 2 patients and one of these patients accepted re-surgery with diode laser but the other refused re-surgery and received radiotherapy. In the patient who was re-operated with diode laser, the margins were free of tumor at the second operation and the patient was followed thereafter on a routine basis. The patient who received radiotherapy had not showed any evidence of recurrence.

The involvement of the A-com was present in 13 (22%) of the patients. The distribution of T stages of A-com involvement is given in Table 1. During the follow-up period, in 8 of these patients, granulation tissue or synechia developed at the anterior part of the larynx. Second look operation was performed for these patients and the granulation tissue (Figure 1) or the synechia was removed with the help of the diode laser. Two of the patients with granulation tissue were demonstrated to have local recurrence on histopathological examination, but the margins were free of tumor following second look operation and they were taken on a

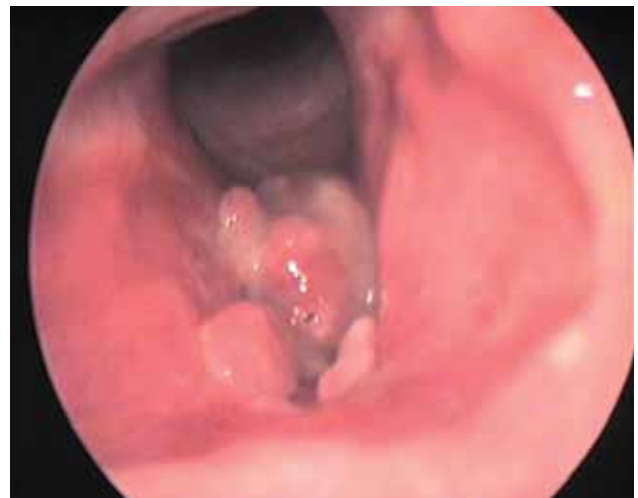

Figure 1. Granulation tissue involving the anterior commissure region following transoral laser microsurgery

Table 1. Distribution of anterior commissure involvement and complications for different T stages

	T1a	T1b	T2	T3	Total
A-com involvement	3	4	6	-	13
Dental injury	2	-	1	-	3
Bleeding	-	-	-	-	-
Intraoperative Fire	-	1	-	-	1
Infection	1	1	2	1	5
Cutaneous emphysema	-	-	-	2	2
Perichondritis / LS	-	-	2	-	2
Tracheostomy	-	2	3	2	7
Aspiration	-	1	1	-	2
A-com GT / synechia	2	2	4	-	8

A-com: Anterior commissure, GT: Granulation tissue, LS: Laryngeal stenosis

routine follow-up, with no evidence of recurrence thereafter. Two patients with web formation were reoperated with TLM.

Local recurrence was encountered in 5 (8%) patients (1 case with T1a, 3 with T2 and one patient with T3 primary tumor at the initial presentation). As stated above, 2 of these local recurrences were explored during the second look operation carried out for the granulation tissue involving the region of anterior commissure. The remaining 3 cases of recurrence were evident as discrete masses on laryngeal endoscopy performed during the follow-up period. All the recurrences appeared in the first year following primary surgery. In one of these patients, complete removal could not be achieved and radical surgery (total laryngectomy) was needed. The other cases of local recurrence were treated by resurgery with diode laser except one in which the patient refused surgery of any type and hence received radiotherapy. This latter patient and the other in whom total laryngectomy was performed are in follow-up with no evidence of local and/or regional recurrence.

At the initial presentation, cervical lymph nodes were involved in 4 patients and staged as N1 (ipsilateral, solitary and less than 3 cm in diameter). Therapeutic neck dissection was performed at the same time as the laser treatment of the primary tumor in these 4 patients. Histopathological examination confirmed the diagnosis of cervical metastasis. During the course of the follow-up period, 2 patients demonstrated cervical recurrence (N1 and N2b) and neck dissection was performed for both of these patients. None of these patients showed evidence of recurrence thereafter.

Intraoperative complications were rare. Dental injury was seen in 3 patients. In one patient, intraoperative laser-induced fire occurred due to thermal injury of the laser on the intubation tube. Tracheostomy was performed in the operating room for this patient together with another patient who had T3 tumor, and a relatively wider excision was performed. In both the intraoperative and the postoperative periods following surgery, no significant bleeding or airway compromise was encountered. Two patients developed cutaneous emphysema which resolved in one day without intervention. In the postoperative period, infection and foul smelling halitosis developed in 5 patients in whom relatively more extended laser surgery was performed. These infections were responsive to appropriate antibiotic therapy but in one patient the thyroid cartilage was exposed (Figure 2). This patient required a second look operation and the exposed part of the thyroid cartilage was resected transorally, but the development of laryngeal stenosis could not be prevented. Tracheostomy was performed for this patient and the management of the laryngeal stenosis was postponed. However, the patient did not show any evidence of recurrence. Apart from this patient, laryngeal stenosis was seen in another patient with T2 primary tumor at the initial presentation in whom tracheostomy was performed again. In 2 patients, tracheostomy and feeding tubes were needed for intractable aspiration. However, these patients were decannulated after 2-3 months since successful swallowing without aspiration was achieved. The overall rate of tracheostomy was 10% (7 patients).

The local recurrence rate was 8% and regional recurrence rate was 3%. One patient was salvaged via total laryngectomy, laryngeal preservation rate was 98%. 2 patients received radiotherapy, one immediately following TLM for margin positivity and the other for local recurrence as a salvage treatment.

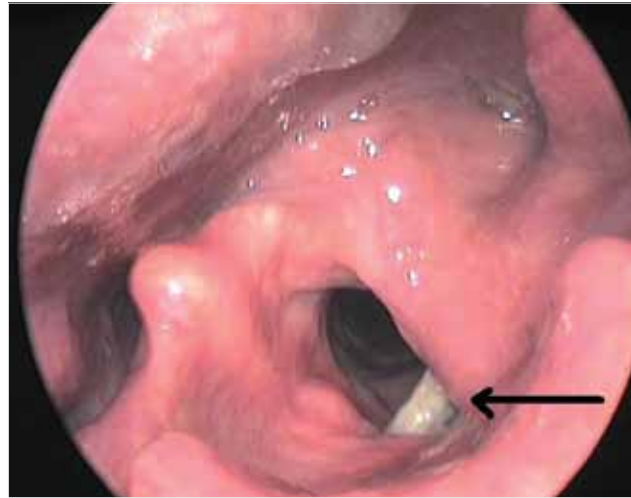


Figure 2. Exposure of the inferior border of the thyroid cartilage (arrow) following transoral laser microsurgery

Discussion

Transoral laser microsurgery has gained an important role in the treatment of laryngeal cancer (9). Especially for early glottic cancers, open surgical techniques are being superseded by transoral approaches (10). Ideally, the treatment for these cancers should have high cure rates, preserving voice quality as much as possible, and should not necessitate a tracheostomy (11,12). The transoral approach also has the advantage of short hospitalization and lower incidence of complications, preserving the choice of open surgery and/or radiotherapy whenever needed (4). Furthermore, TLM was also reported to be a valid treatment strategy for organ preservation in advanced laryngeal carcinomas with low morbidity and mortality and excellent oncologic and functional results (4).

In the practice of otolaryngology, diode lasers are being effectively used for both contact and noncontact modes (11). As the power output of the diode lasers increased and coupling of the diode laser with optical fibers became possible over the last 25 years, clinical applications of the diode lasers has widened. Nonetheless, the output power of the diode laser has a maximum of about 60 W, which is less than that of other laser types (11). The portability and functional diversity of the diode laser make it a reasonable alternative to conventional lasers (13).

Transoral laser treatment of the glottic carcinomas involving the A-com has an important drawback which should be kept in mind. A-com is considered as one of the barriers against the spread of cancer, but the lack of perichondrium may also facilitate cartilage invasion of the cancer (8). It is generally accepted that the presence of a dense (Broyle) ligament prevents spread of early carcinomas, but once it is invaded it provides a path for supraglottic and/or subglottic extension (1). The resection of tumors involving the anterior commissure may lead to postoperative granulation tissue and/or synechia formation which necessitate a second-look operation. A second-look operation may lead to early detection and treatment of local recurrences (8). A-com involvement is associated with a higher rate of local recurrence (14, 15). A-com is a difficult region to assess, which may lead to understaging of the tumor and inadequate exposure during surgery. Radiotherapy is also considered less effective for A-com tumors (1). In this study, the ratio of local recurrence in patients with anterior commissure was 15% (2

of 13 patients), whereas in patients without anterior commissure involvement, the local recurrence rate was 6% (3 of 45 patients) ($p>0.05$). The second-look operations allowed for early detection of recurrences, especially in patients with anterior commissure involvement. The importance of second-look operations was previously confirmed by Roh JL et al. (8) Second-look surgery allowed for both more detail examination of the larynx and histopathological assessment of the suspected lesion. In our series, 13 second-look operations were performed: 8 for granulation tissue/synechia at the A-com, one for margin positivity, 3 for appearance of mass lesions away from the A-com and one for thyroid cartilage exposure. The ratio of second-look operations was higher for cases with A-com involvement (61%), than those without A-com involvement (11%).

The rate of peri- and postoperative complications following TLM is considered relatively low. The incidence of these complications vary according to the size of the tumor and the extent of resection (5). Postoperative bleeding is known as the most frequent complication, however, we did not encounter significant postoperative bleeding in our series. It is of paramount importance to establish an effective intraoperative hemostasis to prevent postoperative bleeding, which may be troublesome. Perichondritis and chondronecrosis are among other less frequent complications which can be treated by laser surgical ablation and/or antibiotic therapy. Cartilage exposure and accompanying chondronecrosis appeared in one of our patients and was managed by laser surgical excision of the exposed necrotic part of the cartilage. Unfortunately, this patient developed laryngeal stenosis and needed tracheostomy for airway control. Laryngeal stenosis is a rare complication of TLM, reported as 2.3% by previous reports which is similar to our series (3%) (5). Cartilage exposure and/or resection may lead to perichondritis and laryngeal stenosis.

Preserving the quality of voice is one of the primary goals in the treatment of early glottic carcinomas. Voice quality is superior in patients treated with laser or radiotherapy compared to open surgical procedures (14). However, the advantages of the TLM favor its use instead of radiotherapy, which has the disadvantages of a prolonged time of treatment, mucosal damage and long term side effects such as xerostomia (11). However, radiotherapy should also be discussed with the patient. On the other hand, although the open surgical procedures were proved to offer better surgical outcomes for anterior commissure involvement, the intrinsic disadvantages may preclude the use of open surgery which include longer hospitalization, inferior voice quality, postoperative pain and edema and disruption of the thyroid framework (11).

Conclusion

Second look operations seem to be an integral part of the follow-up period following TLM of the glottic cancers, especially those involving the A-com. It provides not only early detection but also

treatment of the recurrence. Serious side effects of conventional surgery and radiotherapy on the swallowing and speech functions also favor the use of TLM.

Conflict of Interest

No conflict of interest was declared by the authors.

References

1. Armstrong WB, Vokes DE, Maisel RH. Malignant tumors of the larynx. In: Flint PW, Haughey BH, Lund VJ, et al. editors. Cummings Otolaryngology Head & Neck Surgery. Fifth edition. Vol 2. Philadelphia: Mosby Elsevier; 2010.p.1482-511. [\[CrossRef\]](#)
2. McWhorter AJ, Hoffman HT. Transoral laser microsurgery for laryngeal malignancies. *Curr Probl Cancer* 2005; 29: 180-9. [\[CrossRef\]](#)
3. Vilaseca-González I, Bernal-Sprekelsen M, Blanch-Alejandro JL, Moragas-Lluis M. Complications in transoral CO2 laser surgery for carcinoma of the larynx and hypopharynx. *Head Neck* 2003; 25: 382-8. [\[CrossRef\]](#)
4. Hinni ML, Salassa JR, Grant DG, Pearson BW, Hayden RE, Martin A, et al. Transoral laser microsurgery for advanced laryngeal cancer. *Arch Otolaryngol Head Neck Surg* 2007; 133: 1198-204. [\[CrossRef\]](#)
5. Ellies M, Steiner W. Peri- and postoperative complications after laser surgery of tumors of the upper aerodigestive tract. *Am J Otolaryngol* 2007; 28: 168-72. [\[CrossRef\]](#)
6. Bradley PJ, Rinaldo A, Suárez C, Shaha AR, Leemans CR, Langendijk JA, et al. Primary treatment of the anterior vocal commissure squamous carcinoma. *Eur Arch Otorhinolaryngol* 2006; 263: 879-88. [\[CrossRef\]](#)
7. Pearson BW, Salassa JR. Transoral laser microresection for cancer of the larynx involving the anterior commissure. *Laryngoscope* 2003; 113: 1104-12. [\[CrossRef\]](#)
8. Roh JL, Kim DH, Park CI. The utility of second-look operation after laser microresection of glottic carcinoma involving the anterior commissure. *Laryngoscope* 2008; 118: 1400-4. [\[CrossRef\]](#)
9. Preuss SF, Cramer K, Klusmann JP, Eckel HE, Guntinas-Lichius O. Transoral laser surgery for laryngeal cancer: outcome, complications and prognostic factors in 275 patients. *Eur J Surg Oncol* 2009; 35: 235-40. [\[CrossRef\]](#)
10. Grant DG, Salassa JR, Hinni ML, Pearson BW, Hayden RE, Perry WC. Transoral laser microsurgery for untreated glottic carcinoma. *Otolaryngol Head Neck Surg* 2007; 137: 482-6. [\[CrossRef\]](#)
11. Ferri E, Armato E. Diode laser microsurgery for treatment of Tis and T1 glottic carcinomas. *Am J Otolaryngol* 2008; 29: 101-5. [\[CrossRef\]](#)
12. Peretti G, Nicolai P, Piazza C, Redaelli de Zinis LO, Valentini S, Antonelli AR. Oncological results of endoscopic resections of Tis and T1 glottic carcinomas by carbon dioxide laser. *Ann Otol Rhinol Laryngol* 2001; 110: 820-6.
13. Newman J, Anand V. Applications of the diode laser in otolaryngology. *Ear Nose Throat J* 2002; 81: 850-1.
14. Ambrosch P. The role of laser microsurgery in the treatment of laryngeal cancer. *Curr Opin Otolaryngol Head Neck Surg* 2007; 15: 82-8. [\[CrossRef\]](#)
15. Steiner W, Ambrosch P, Rödel RM, Kron M. Impact of anterior commissure involvement on local control of early glottic carcinoma treated by laser microresection. *Laryngoscope* 2004; 114: 1485-91. [\[CrossRef\]](#)