

Swimming - Pool Granuloma*

**Dr. Şerife Günel KARAGÜLLE (1), Dr. Ümmühan KİREMİTÇİ (1), Dr. Elif TOPÇU (1),
Dr. Aslı TURGUT ERDEMİR (1), Dr. Nuri Osman HÜTEN (2), Dr. Melin Özgün GEÇER (2)**

ÖZET

Yüzme havuzu granulomu, hasarlanmış derinin, normalde saprofit olarak bulunan Mikobakterium marinum olan su ile temasını izleyen kronik granulomatöz bir enfeksiyonudur. Bu atipik mikobakteri enfeksiyonu immunsupresif hastalar dışında asla sistemik bir hastalığa neden olmazlar. Sol elinin üzerinde yüzme havuzu granulomu olan 58 yaşında bir hasta sunulmaktadır. 8 yıl önce akvaryumdaki balıklarının yemesi için midye kabuğu kırarken elini yaralamış ve annuler, verrüköz, granülatöz lezyonlar gelişmiştir. Biz bu hastalık için risk faktörlerini ve özelliklerini araştırdık ve literatürü gözden geçirdik.

Anahtar Kelimeler: *Yüzme havuzu granulomu, Mikobakterium marinum*

SUMMARY

Swimming - Pool Granuloma

The swimming-pool granuloma is a chronic granulomatous infection following injury of skin with exposure to water where Mycobacterium marinum is present as a normal saprophyte. This atypical mycobacteria infection is never causes a systemic disease except immunosuppressive patients. A 58-year old male patient presented with swimming-pool granuloma on the left hand. Eight years ago; he injured his hand while he was splitting the mussel crust to feed his fishes in the aquarium and annular, verrucous, granulomatous lesions have been developed. We reviewed the literature and update the clinical characteristics and risk factors for these diseases.

Key Words: *The swimming-pool granuloma, Mycobacterium marinum*

INTRODUCTION

Swimming pool granuloma (SPG) which is caused by *M. marinum* (M.m.) is chronic infectious disease of the skin^{1,2}. M.m. infection occurs following of skin trauma in fresh or salt water and usually presents as a localized granuloma or sporotrichotic lymphangitis (1-3). Most commonly, the lesions are solitary and may be scaly or verrucous papules (1,2-4).

Herein we report a case of SPG and discuss the clinical characteristics and risk factors of the disorder in view of the medical literature.

CASE REPORT

A 58-years old male patient presented an annular, verrucous border, violaceous plaque with central

spontaneous clearing on the dorsum of the left hand (Figure 1). Eight years ago; he injured second finger of his hand while he was splitting mussel crust to feed his fishes in the aquarium. Swelling, inflammation and crusted lesion have been developed on his finger. After 3 weeks, it recovered as a firm verrucous nodular lesion. He had no subjective complaint. After applied cryotherapy with misdiagnosed as wart, there was not any progression approximately for 6 months. Moreafter; the lesion began to progress towards dorsum of the hand as annular plaque with verrucous border. Three year ago; punch biopsy specimen had been received considering swimming pool granuloma but histopathological findings were inadequate and a new biopsy was suggested. The patient refused new biopsy and applied different physicians. Some physicians prescribed antimycotic creams due to clinic appearance like tinea corporis. We considered swimming pool granuloma because of clinic appearance and history. Histopathologic investigation concluded as a non-caseous tuberculoid inflammatory infiltrate in the dermis (Figure 2). We isolated *M. marinum* with polymerase chain reaction (PCR) method and in Löwenstein-Jensen and

SSK İstanbul Eğitim Hastanesi Dermatoloji (1) ve Patoloji Kliniği (2), İstanbul

** Bu olgu 2-6/10/2002'de Prag'da Yapılan 11.EADV Kongresinde poster olarak sunulmuştur.*

Bactec Middlebrook media from biopsy specimens. PPD test was positive. Chest X-ray was normal. Bacillus Koch (BK) in mucus was negative. Systemic examination was normal. Routine laboratory investigations were normal. After 2 monthly therapy with doxycycline (200 mg/day) improved the lesions dramatically.

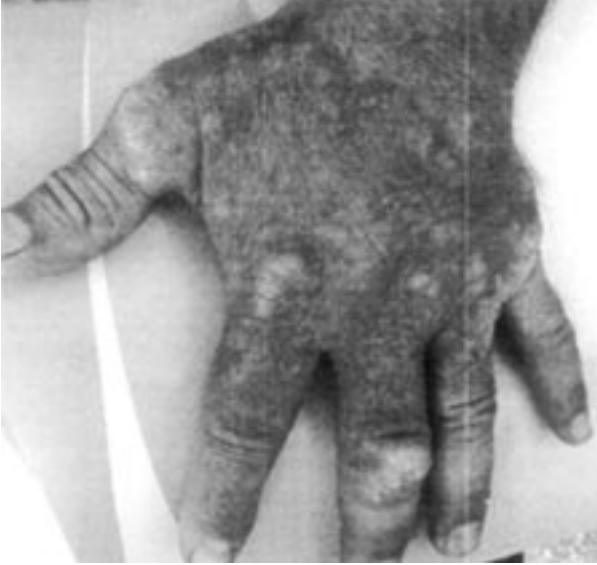

Figure 1: An annular , verrucous borders , violaceous plaque on dorsum of the left hand .

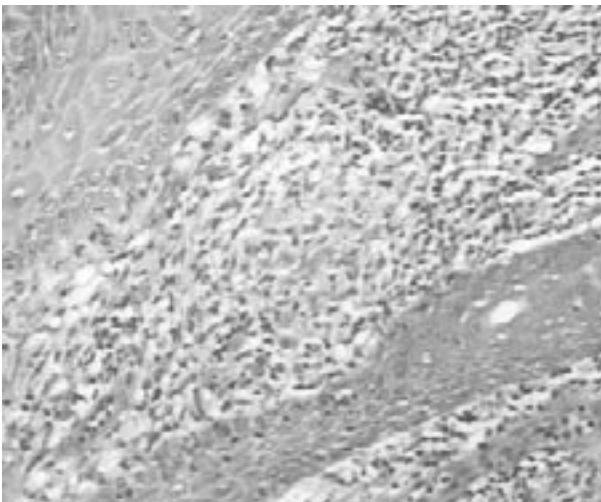


Figure 2: A non-caseous tuberculoid granuloma between of the rete ridges. Hematoxylen+Eosine (H+E)X 200

DISCUSSION

Mycobacterium marinum (M.m.) is an atypical *Mycobacterium* commonly found in both salt and fresh water environments such as swimming pool, aquariums, beaches, rivers, lakes, and old wells (1-7). Salt and

fresh water fish and other organisms have been reported as vectors for the disease (7). Fishermen and workers who process saltwater fish , workers who clean saltwater aquariums, immunocompromised patients (increased risk of disseminated infection) and home aquarium owners are at increased risk for infection (3).

M.m. was first isolated from a saltwater fish in 1926, but not until 1951 was it demonstrated that this organism was able to infect people who frequented swimming pools (4-6). For this reason, the skin infection was termed swimming-pool granuloma (4-6).

This pathogen is classified in Runyon group 1 and is a photochromogen, which means it produces pigment when cultured and exposed to light (1-3,5). Culture growth occurs over 7-14 days and organism grows better at 32°C in Löwenstein-Jensen medium; therefore, cooler extremities are affected more often than central sites (1-3,5).

Infection often follows abrasions to an extremity occurring in nonchlorinated water and lesions appear at the site of trauma (1-7). An indolent lesion usually starts about 3 weeks after exposure as a small papule located on the hands, knees, elbows, or feet (1-7). The body temperature in the acral sites is probably more similar to that optimal (32°C) for growth of the M.m. organisms (5). The infection is characterized by the presence of a painless papule, itchy, warty nodule or plaque, which is usually solitary and often ulcerates (1-7). Sometimes, the lesion softens, with discharge of purulent material (4). Sporotrichoid form(% 20-40), with one or more nodules along the line of lymphatic drainage, are not uncommon(1-7).

Patients may have deeper involvement, with tenosynovitis, septic arthritis, and osteomyelitis of the underlying bone(1-7). Regional lymph glands may be slightly enlarged but never break down (6). An upper extremity is affected in nearly 90% of cases (4). Patients also can present with an erythematous plaque on their hands (1-7). Occasionally lesions are multiple or disseminated, especially in the immunosuppressed but this can also occur in the immunologically normal (3-7). In 50-80% of the cases the patients have a positive PPD test (1-7). Spontaneous resolution may occur in 10-20% of patients after a period of many months (1,3,6,7).

Histopathology of younger lesions shows epidermal hyperkeratosis, acanthosis, and mixed dermal infiltrate, or, possibly, frank suppuration (1,3,5). Older lesions may present as organized granulomas; however, caseation is uncommon (1-4). Organisms are rarely found in specimens from normal hosts, multiple acid-fast organisms are often seen in biopsies from immunocompromised patients (1-7).

The diagnosis is based on the clinicohistopathologic

findings, but a history of contact with water of aquariums and swimming pools is helpful (5). Tissue culture is essential for accurate diagnosis (2-7). *M.m.* grows on Löwenstein-Jensen and Bactec Middlebrook media (4). Skin tests using antigens specific to *M.m.* are of little value (5).

The differential diagnosis includes sporotrichosis, tuberculosis verrucosa cutis, warts, cellulitis, deep mycoses, cutaneous leishmaniasis, tularemia, cat-scratch disease, foreign body granuloma, sarcoidosis, squamous cell carcinoma and infections with other mycobacteria such as *M. kansaii*, *M. chelonae* and *M. goodii* (1-7).

Therapy is not well defined (1-7). Like most atypical mycobacteria, *M.m.* is poorly susceptible to antituberculous drugs (eg, isoniazid, streptomycin and para-aminosalicylic acid) (3). Minocycline, 200 mg/day for 1 to 2 months, is the treatment of choice. Trimethoprim-sulfamethoxazole, doxycycline, clarithromycin (1-7), levofloxacin and cephalosporin have all been used with different doses and treatment schedules (1-7). Treatment with 600mg of rifampin and 800 mg of ethambutol daily may be curative in those patients who do not respond to the tetracyclines or sulfa drugs (1-7). An increase in local temperature, through immersion of the afflicted extremity in hot water, could help to resolve the clinical features 2,5. In some cases surgical debridement of lesions may be necessary (3-5,7).

The public health authorities should be notified when a public source of infection is identified and other cases should be looked for (5). Maximum chlorination of swimming pools is effective (5). Fish fanciers are seldom aware of the risk of mycobacterial infection from their hobby (5). Simple preventative measures, such as the use of gloves, or at least the covering of cuts and grazes, could reduce the incidence of infections considerably (5).

Swimming-pool granuloma is not common. It has potential to recover by itself although misdiagnosis possibility. The low compliance of patients from the lesions may delay to apply to doctors. In this case; the four reasons of the delaying of our patient's recovery are that, The lack of histopathologic diagnosis (three years ago), mistreatment, neglectfulness of the patient and continuous contamination because of aquarium at home. Using of gloves during the care of aquarium has been advised and the patient has recovered dramatically after 2 months doxycycline treatment.

- Diseases of the Skin Clinical Dermatology. 9th ed. Philadelphia, W.B. Saunders Company. 2000:426-7.
2. **Tomecki KJ, Dijkstra JWE. Treponemes, Rickettsia, and Mycobacteria:** Principles and Practice of Dermatology. Sams WM, Lynch PJ. First ed. New York, Churchill Livingstone. 1990;165-6.
 3. **Kiel RJ:** Mycobacterium Marinum. eMedicine Journal, 4,2002;3(1).MEDLINE
 4. **Hood AF:** Diagnosis: Mycobacterium Marinum. Archives of Dermatology 1998;134(3). MEDLINE
 5. **Savin JA . Mycobacterial Infections:** Rook/ Wilkinon/ Ebling .Textbook of Dermatology. Champion RH., Burton JL., Ebling FJG. 5th.ed. Oxford, Blackwell Sci. Pub.1992;1057-8.
 6. **Tappeiner G, Wolff K.** Tuberculosis and Other Mycobacterial Infections. Fitzpatrick's Dermatology in General Medicine. Freedberg IM, Eisen AZ, Wolff K, et al., 5th ed., New York, McGraw Hill. 1999; 2288-9.
 7. **Kullavanijaya P, Sirimachan S, Bhuddhavudhikrai P:** Mycobacterium marinum cutaneous infections acquired from occupations and hobbies. Int J Dermatol 1992; 32(7): 504-7.
-

REFERENCES

1. **Odom RB, James WD, Berger TG .** Andrews'