






Insufficiency of YAG Laser Iridotomy to Prevent Pupillary Block Glaucoma in a Microspherophakic Patient with Weill-Marchesani Syndrome

Weill-Marchesani Sendromlu Bir Mikrosferofaki Olgusunda Pupil Bloğu Glokomunu Önlemede YAG-Lazer İridotominin Yetersizliği

Serpil Yazgan , Tuba Çelik , Erkan Çelik 

Abstract / Öz

Microspherophakia is a developmental disorder of the lens characterized by a small and spherical lens. Defective development of the lens fibers during embryogenesis was thought to be responsible for the abnormal size and shape of the lens. Weill-Marchesani syndrome (WMS) is the most common syndrome accompanying microspherophakia. The spherical shape of the lens increases the refractive power of the lens and leads to high myopia. Furthermore, due to zonular weakness, the small and spherical lens can easily move forward and lead to a pupil block. In this case report, we discussed a case of WMS with microspherophakia in which the yttrium-aluminium-garnet (YAG) laser iridotomy had been performed on multiple areas to prevent pupillary block, but glaucoma progressed despite multiple laser iridotomy treatments. We stressed that if YAG laser iridotomy is implemented as first-line treatment in microspherophakic patients with WMS, the patients should be closely monitored. We also emphasized that if glaucoma progression continues despite the effective YAG laser iridotomy, the ophthalmologist should not insist on YAG laser treatment, and surgical lens removal option should be considered.

Keywords: Microspherophakia, pupillary block glaucoma, Weill-Marchesani syndrome, yttrium-aluminium-garnet laser iridotomy

Mikrosferofaki küçük ve sferik lens ile karakterize gelişimsel bir lens hastalığıdır. Embriyogenezis sırasında lens fibrillerinin defektif gelişiminin lensin anormal şekil ve büyüklüğünden sorumlu olduğu düşünülmüştür. Weill-Marchesani Sendromu (WMS) mikrosferofakinin eşlik ettiği en yaygın sendromdur. Lensin sferik biçimi lensin refraktif gücünün artmasına katkıda bulunur ve yüksek miyopiye yol açar. Ayrıca zonüllerin zayıf olmasından dolayı küçük ve sferik lens kolayca öne doğru hareket edebilir ve pupil bloğuna yol açabilir. Bu olgu sunumunda, pupil blok glokomunu önlemek için çok sayıda alana yttrium-aluminium-garnet (YAG) lazer iridotomi uygulanmış ancak çoklu lazer iridotomi tedavisine rağmen glokom progresyonu devam eden bir mikrosferofakili WMS olgusunu tartıştık. Biz bu olgu ile dikkat çekmek istedik ki, eğer WMS'li mikrosferofakik olgularda ilk tedavi seçeneği olarak YAG lazer iridotomi uygulanırsa hastalar yakından takip edilmelidir. Yine vurgulamak istedik ki etkin bir YAG lazer iridotomiye rağmen glokom progresyonu devam ederse oftalmolojist yeni YAG lazer iridotomi tedavilerinde ısrar etmemelidir ve cerrahi lens çıkarılması gibi alternatif tedaviler düşünülmelidir.

Anahtar Kelimeler: Mikrosferofaki, pupil blok glokomu, Weill-Marchesani sendromu, yttrium-aluminium-garnet lazer iridotomi

Introduction

Weill-Marchesani syndrome (WMS) is a rare condition presenting mostly an autosomal recessive inheritance, but the genetic pattern has not yet been clarified. In addition, a specific diagnostic test for WMS has not yet been reported. It is clinically diagnosed and can be confirmed by genetic testing (1). The characteristic skeletal system findings of WMS are short stature, brachydactyly, and joint stiffness; the characteristic ocular abnormalities of WMS are microspherophakia, ectopia of lentis, severe myopia, and glaucoma. The skeletal findings generally do not require treatment, but ocular findings are very important in WMS (1, 2). Microspherophakia in which the crystalline lens assumes a spherical shape with an increased anteroposterior diameter and reduced equatorial diameter is seen in 94% WMS cases. In addition to microspherophakia, lenticular myopia, short axial length, shallow anterior chamber, and ectopia lentis are also seen in WMS (3). WMS is the most common syndrome associated with microspherophakia (2). Lens subluxation increases progressively and reaches to 90% between the third and fourth decades (4, 5).

In this case report, we discussed a WMS patient with microspherophakia who had been subjected to multiple prophylactic YAG laser iridotomy on at least seven different areas to prevent pupillary block glaucoma, but glaucoma progression continued despite the laser iridotomy treatment.

Case Report

A 36-year-old woman was admitted to the ophthalmology clinic with complaints of glaucoma in both eyes. Autorefractometry measurements were -9 diopter in the right eye and -11 diopter in the left eye. The best-corrected Snellen visual acuity was 0.8 in the right eye and 0.5 in the left eye. Intraocular pressure values were 14 mmHg in the right eye and 18 mmHg in the left eye. A topical timololol maleate and brimonidine fix combination (Combigan, Allergan, Ireland) had been given

ORCID IDs of the all authors: S.Y. 0000-0001-6401-6376; T.Ç. 0000-0002-2684-7491; E.Ç. 0000-0002-0750-6755

This study was presented as a poster at the 50th National Congress of Turkish Ophthalmology Society (9-13 November, 2016, Antalya, Turkey).

Department of Ophthalmology, Bülent Ecevit University, School of Medicine, Zonguldak, Turkey

Yazışma Adresi

Address for Correspondence:

Serpil Yazgan

E-mail: serpily80@gmail.com

Geliş Tarihi/Received: 09.06.2017

Kabul Tarihi/Accepted: 22.10.2017

© Telif Hakkı 2018 Makale metnine istanbulmultipdergisi.org web sayfasından ulaşılabilir.

© Copyright 2018 by Available online at istanbulmedicaljournal.org

in both eyes by another clinic. During the slit-lamp examination, six laser iridotomy holes in the right eye and eight laser iridotomy holes in the left eye were observed (Figure 1a-b). She had microspherophakia and phacodonesis in both her eyes. In the fundus examination, cup-to-disc ratio was 0.6 in the right eye and 0.9 in the left eye, and optic discs were slightly tilted (Figure 2 a, b). Axial lengths were 22.08 mm in the right eye and 22.55 mm in the left eye.

We assumed she had WMS due to high myopic refractive values despite shorter axial lengths, microspherophakic appearance, and phacodonesis in both eyes. Furthermore, skeletal findings included short stature (1.56 meters), brachydactyly (Figure 3), and joint stiffness. However, we could not perform genetic test to confirm the disease.

We detected a rapid visual field loss and severe retinal nerve fiber layer decrease resulting from pupillary block glaucoma despite multiple YAG laser iridotomy holes in the left eye (Figure 4a and b). Informed consent was obtained from the patient. We suggested a surgical lens extraction to the patient. She preferred that her ocular surgery be done in Istanbul because of her first-degree relatives living there. The patient was referred to the hospital of her choice.

Discussion

Most of the genetic studies state that fibrillin-1 or fibrillin-3 gene mutation is detected in some WMS cases. It is believed that a microspherical lens causes elongation, weakness, and breaking of zonules over time, leading to dislocation of the lens (4). The dislocation of microspherophakic lens provoked pupillary block glaucoma in 80% of the WMS cases (4-6). In WMS, because of microspherophakia, the risk of pupillary block glaucoma is much higher than other congenital lens dislocation syndromes, such as homocystinuria and Marfan syndrome (6). Reportedly, most of the patients with WMS presented with initial symptoms of acute angle-closure glaucoma, while WMS had not yet been diagnosed (7). Refractory glaucoma secondary to iridocorneal angle abnormalities and arteriovenous malformation are very rare conditions and not specific for WMS (3, 8).

The mainstream treatment of microspherophakia is prevention of secondary angle-closure glaucoma. However, the best method to prevent it is controversial. It is known that anti-glaucomatous medical treatment has been unsuccessful (6, 9). As an alternative therapeutic approach, application of YAG laser peripheral iridotomy because of a low complication rate followed by use of miotic eye drops to prevent forward dislocation of the lens have been

suggested for microspherophakia. However, it is known that miotic eye drops may cause an increase in contraction of the ciliary body, thus leading to increased zonular loss. In addition, miotic eye drops can trigger the development of pupil block causing the lens to be pushed forward. In addition, the use of mydriatic eye drops is inconvenient because they facilitate the anterior chamber lens dislocation through a dilated pupil (6). Although prophylactic YAG laser peripheral iridectomy is recommended by many authorities (6, 10), acute angle-closure glaucoma due to pupillary block has been seen despite the use of bilateral YAG laser iridotomy in the literature (5, 9).

Surgical lens extraction is known to be an effective method for the prevention of pupillary block glaucoma due to lens dislocation into the anterior chamber (11). But small capsular bag and large zonular weakness lead to difficulties with surgeries in such patients.

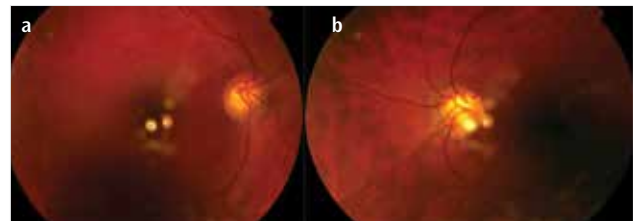

Figure 2. a,b. (a) Colored fundus image of the right eye; tilted disc is seen, while the cup-to-disc ratio is normal. (b) Colored fundus image of the left eye; tilted disc is seen with glaucomatous optic atrophy close to full atrophy, while cup-to-disc ratio is 0.9

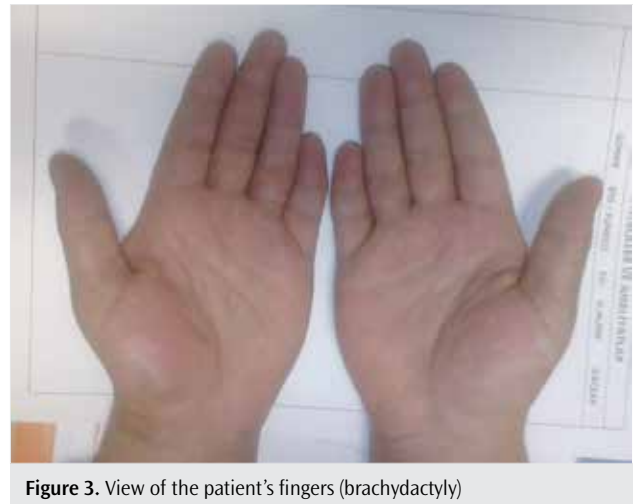

Figure 3. View of the patient's fingers (brachydactyly)

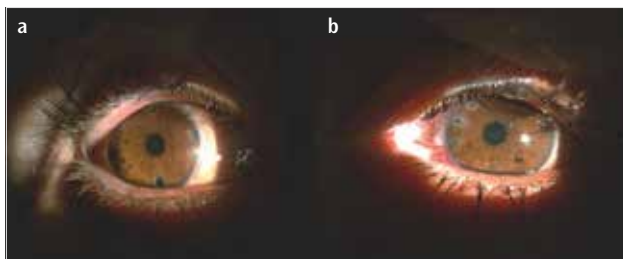


Figure 1. a,b. Right (a) and left (b) anterior segment images; anterior chambers are shallow, and multiple peripheral laser iridotomy holes are seen

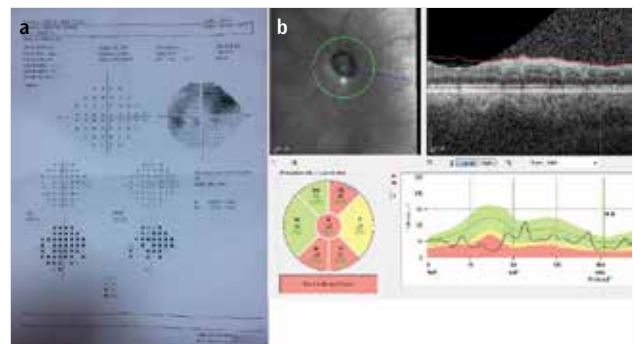


Figure 4. a,b. (a) Visual field test of the left eye; arcuate scotoma is seen. (b) Retinal nerve fiber layer (RNFL) analysis of the left eye by optical coherence tomography; extensive RNFL loss is seen

Lens extraction and intraocular lens implantation without the use of capsular tension ring may cause early or late postoperative capsular contraction syndrome (10, 12). Moreover, intracapsular lens implantation may fall through because of small capsular bag, vitreous loss, and surgical complications related to vitreous loss (13). Iris-claw anterior chamber lens implantation may lead to severe endothelial loss and iridocorneal synechia due to shallow anterior chamber in such patients (14). Cionni et al. (15) reported successful results of modified capsular tension ring (MCTR) and a posterior chamber intraocular lens (PC IOL) implantation in patients with congenitally subluxated crystalline lenses, including patients with WMS. The rate of pupillary block glaucoma development in WMS cases reached 100% because of microspherophakia and zonular weakness in the third and fourth decades. Furthermore, the rate of legal blindness in these patients was approximately 30% (6, 7, 12).

Conclusion

As a result, we can say that if YAG laser iridotomy is considered as a first-line treatment in microspherophakic patients with WMS, they should be closely monitored. If glaucoma progression continues despite the effective YAG laser iridotomy, the ophthalmologist should not insist on new laser iridotomies. Moreover, unnecessary iridotomy applications may increase zonular weakness and lens dislocation in such patients. We should not stress on the controversial or partially useful methods to prevent pupillary block glaucoma, particularly in patients with severe glaucomatous damage in one eye. According to literature, microspherophakic lens extraction and MCTR/PC IOL implantation seem to be the best surgical methods in microspherophakic patients with WMS.

Informed Consent: Informed consent was obtained from the patient who participated in this study.

Peer-review: Externally peer-reviewed.

Author Contributions: Concept - S.Y.; Design - S.Y., E.Ç.; Supervision - S.Y., E.Ç.; Resource - E.Ç.; Materials - S.Y., E.Ç., T.Ç.; Data Collection and/or Processing - S.Y., E.Ç.; Analysis and/or Interpretation - S.Y., T.Ç.; Literature Search - S.Y., T.Ç.; Writing - S.Y.; Critical Reviews - S.Y., T.Ç.

Conflict of Interest: No conflict of interest declared by the authors.

Financial Disclosure: The authors declared that this study has received no financial support.

Hasta Onamı: Bilgilendirilmiş hasta onamı bu çalışmaya katılan hastadan alınmıştır.

Hakem Değerlendirmesi: Dış Bağımsız.

Yazar Katkıları: Fikir - S.Y.; Tasarım - S.Y.; Denetleme - S.Y., E.Ç.; Kaynaklar - E.Ç.; Malzemeler - S.Y., E.Ç., T.Ç.; Veri Toplanması ve/veya İşlemesi - S.Y.,

E.Ç.; Analiz ve/veya Yorum - S.Y., T.Ç.; Literatür taraması - S.Y., T.Ç.; Yazıyı Yazan - S.Y.; Eleştirel İnceleme - S.Y., T.Ç.

Çıkar Çatışması: Yazarlar çıkar çatışması bildirmemişlerdir.

Finansal Destek: Yazarlar bu çalışma için finansal destek almadıklarını beyan etmişlerdir.

References

1. Tsilou E, MacDonald IM. Weill-Marchesani Syndrome. GeneReviews®(Internet). 2007 Nov (updated 2013 Feb 14). Available from: URL: <https://www.ncbi.nlm.nih.gov/books/NBK11114/>.
2. Liebmann JM, Ritch R. Glaucoma associated with lens intumescence and dislocation. Ritch R, Shields MV, Krupin T, editors. St Louis: Mosby; 1996.p.1033-53.
3. Razeghinejad MR, Hosseini H, Namazi N. Biometric and corneal topographic characteristics in patients with Weill-Marchesani syndrome. J Cataract Refract Surg 2009; 35: 1026-32. [CrossRef]
4. Zimmerman TJ, Kooner KS. Clinical Pathway in Glaucoma. 2001; 10: 187-97.
5. Willi M, Kut L, Cotlier E. Pupillary-block glaucoma in the marchesani syndrome. Arch Ophtalmol 1973; 90: 504-8. [CrossRef]
6. Jensen AD, Cross HE, Paton D. Ocular complication in the Weill-Marchesani Syndrom. Am J Ophtalmol 1974; 77: 261-9. [CrossRef]
7. Wright KW, Chrousos GA. Weill-MARCHESANI Syndrome with bilateral angle-closure glaucoma. J pediatr Ophtalmol Strabismus 1985; 22: 129-32.
8. Derosé CJ, Jeffrey A. Uncontrolled glaucoma secondary to an arterio-venous malformation in a Weill-Marchesani patient. Optometry 2001; 72: 641-8.
9. Senthil S, Rao HL, Hoang NT, Jonnadula GB, Addepalli UK, Mandal AK, et al. Glaucoma in microspherophakia: presenting features and treatment outcomes. J Glaucoma 2014; 23: 262-7. [CrossRef]
10. Allingham RR, Shields MB, Damji KF, et al. Shield's Textbook of Glaucoma. 6th ed. Wolters Kluwer; 2011.p.286.
11. Seetner AA, Crawford JS. Surgical Correction of lens dislocation in children. Am J Ophtalmol 1981; 91: 106-10. [CrossRef]
12. Dufay-Dupar B, Blumen OE, Rodallec T. Rare complication in microspherophakia surgery: early capsular contraction. J Fr Ophtalmol 2007; 30: 1023. [CrossRef]
13. Taylor JN. Weill-Marchesani syndrome complicated by secondary glaucoma. Case management with surgical lens extraction. Aust N Z J Ophtalmol 1996; 24: 275-8. [CrossRef]
14. Burakgazi AZ, Ozbek Z, Rapuano CJ. Long-term complications of iris-claw phakic intraocular lens implantation in Weill- Marchesani Syndrome. Cornea 2006; 25: 361-3. [CrossRef]
15. Cionni RJ, Osher RH, Marques DM, et al. Modified capsular tension ring for patients with congenital loss of zonular support. J Cataract Refract Surg 2003; 29: 1668-73. [CrossRef]

Cite this article as: Yazgan S, Çelik T, Çelik E. Insufficiency of YAG laser iridotomy to prevent pupillary block glaucoma in a microspherophakic patient with Weill-Marchesani syndrome. İstanbul Med J 2018; 19: 73-5.