



# Can The Configuration of Petrous Bone Pneumatization be a Predictor of Tinnitus?

## Petröz Kemik Pnömotizasyon Konfigürasyonu Tinnitusta Belirleyici Olabilir mi?

Abdullah Soydan Mahmutoglu<sup>1</sup>, İrfan Çelebi<sup>2</sup>

**Amaç:** Çalışmamızda petröz kemik pnömotizasyonu ile subjektif pulsatile tinnitus (SPT) arasında olası ilişki varlığını araştırdık.

**Yöntemler:** Ekim 2013 ile Mayıs 2014 tarihleri arasında subjektif pulsatile tinnitusu olan 35 kişinin temporal kemik bilgisayarlı tomografi (BT) incelemeleri değerlendirildi. Kontrol grubu verileri ise kronik sinüzit nedeniyle paranazal sinüs BT'si çekilen, herhangi bir kulak patolojisi ve tinnitus şikayeti olmayan 35 olgunun rekonstrükte petröz kemik görüntülerinin retrospektif olarak değerlendirilmesi ile elde edildi.

**Bulgular:** Toplam 46 SPT'li kulak incelendi. 13 (%28,26) kulakta petröz pnömotizasyon saptandı. 11 olguda pnömotizasyonlar multiple küçük hava hücrelerinden oluşmakta iken iki tanesinde ICA ve koklea arasında ağırlıklı büyük hava hücreleri vardı. Kontrol grubunda tinnitus olmayan 35 kişinin 70 kulağında, 15 (%21,42) petröz pnömotizasyon saptandı ve hepsi küçük hava hücrelerinden oluşmaktaydı. Çalışma ve kontrol gruplarının karşılaştırılmasında petröz pnömotizasyon ve tinnitus arasında istatistiksel anlamlı bir ilişki bulunmadı ( $p>0,05$ ).

**Sonuç:** Biz çalışmamızda petröz pnömotizasyonla tinnitus arasında anlamlı bir ilişki bulmadık. Ancak bilateral pnömotizasyonlu iki olguda tek taraflı tinnitus ile aynı tarafta büyük hava hücresi, tinnitus olmayan diğer kulakta ise küçük hava hücreleri izledik. Petröz apeks pnömotizasyonunda multiple kemik lamella ve hava hücrelerine bağlı birçok arayüz ses dalgalarının yolculukları boyunca kırılma ve yansımalarına yol açarken hiç ya da birkaç ince septa içeren büyük hücre varlığı sesi distorte etmeden iletebileceğini varsayarsak amplifikasyondan ziyade küçük hücreli tarafta büyük hücreye kıyasla ses şiddetinde azalma ve büyük hücreli tarafta rölatif olarak şiddetin normale daha yakın kalmasına bağlı kokleada artmış iletim olarak algılanabilir mi? Bu teorianın doğruluğunu ortaya koymak için geniş serilerde çalışma yapılması gereklidir.

**Anahtar Kelimeler:** Tinnitus, temporal kemik, pnömotizasyon, bilgisayarlı tomografi

**Introduction:** In this study, we tried to evaluate a possible relationship between petrous bone pneumatization and subjective pulsatile tinnitus (SPT).

**Methods:** The temporal bone computed tomographic (CT) images of 35 patients with SPT admitted to our hospital between October 2013 and May 2014 were evaluated. We formed the control group by a retrospective evaluation of the reconstructed images of the petrous bones derived from the paranasal CT scans of 35 patients free of SPT complaints performed because of chronic sinusitis.

**Results:** Overall, 46 ears of patients with SPT were evaluated. Of these, 13 (28.26%) had petrous bone pneumatization. Of these, 11 of them had increased pneumatization formed of small air cells, whereas two had predominant large air cells between internal carotid artery (ICA) and cochlea. In the control group, 15 (21.42%) of 70 ears had petrous bone pneumatization formed of small air cells. On comparing study and control groups, no significant relationship was found between petrous pneumatization and tinnitus ( $p>0.05$ ).

**Conclusion:** In our study, we did not find any significant relationship between pneumatization and tinnitus, but we detected two patients with bilateral pneumatization, who had SPT at the side of pneumatization, which mainly consisted of a unibody large air cell; however, the opposite sides, which consisted of multiple small air cells, were free of tinnitus. For these cases, a question arises whether a combination of thin bony lamellas and tiny air cells together causing multiple interfaces resulting in dispersion and reflection, thus reducing the energy of the sound and existence of a unibody large air cell conducting the sound with relatively less distortion, eventually resulting in not amplification but less interference on the sound can be perceived by cochlea as relatively increased conduction of the blood flow and result in SPT. To prove this theory, a study with a large number of cases in resemblance has to be conducted.

**Keywords:** Tinnitus, temporal bone, pneumatization, computed tomography

ORCID ID of the authors: A.S.M. 0000-0001-7987-0006; İ.Ç. 0000-0003-2562-2482

<sup>1</sup>Department of Radiology, İstanbul Training and Research Hospital, İstanbul, Turkey

<sup>2</sup>Department of Radiology, Şişli Hamidiye Etfal Training and Research Hospital, İstanbul, Turkey

**Yazışma Adresi / Address for Correspondence:**  
Abdullah Soydan Mahmutoglu  
E-mail: asmahmutoglu@yahoo.com

Geliş Tarihi/Received: 15.05.2017

Kabul Tarihi/Accepted: 01.10.2017

© Telif Hakkı 2018 Makale metnine istanbulmedj.org web sayfasından ulaşılabilir.

© Copyright 2018 by Available online at istanbulmedicaljournal.org

## Introduction

Tinnitus is described as an auditory sensation felt in the absence of an external stimulus (1). It affects approximately 12% of the population in Western countries (2, 3). Although audiometric evaluation can be useful to reveal the source of tinnitus (Meniere's disease, otosclerosis, or noise-induced hearing loss), the existence of disabling symptoms causes radiological evaluation to be unavoidable (4, 5). Tinnitus is characterized as objective or subjective and pulsatile or nonpulsatile. Pulsatile tinnitus (PT) harmonizes with the heartbeat of the patient, whereas nonpulsatile tinnitus does not. Tinnitus can be subjective (perceived only by the patient) or objective (can be perceived by others).

Subjective tinnitus is more common than objective tinnitus. PT may be either subjective or objective. As for nonpulsatile tinnitus, it is subjective in most of the cases. Subjective nonpulsatile tinnitus is the most frequently observed type of tinnitus, and most probably the cause is least likely to be treatable (6, 7).

Radiologic studies should follow a full clinical evaluation including neuro-otologic examination with otoscopy and audiologic assessment. The most appropriate imaging technique can be determined after characterization of the tinnitus and detailed clinical evaluation (8-10). The cause of PT is most probably going to be a vascular abnormality or vascular tumor. By virtue of the fact that these vascular lesions often involve the middle ear and otic capsule where MR is less sensitive, computed tomography (CT) becomes more valuable and intravenous contrast administration also facilitates the imaging of vascular structures (11-13).

## Methods

The temporal bone CT images of 35 patients with subjective PT (SPT), who were admitted to our hospital between October 2013 and May 2014, were evaluated. The study group consisted of patients without vertigo, otalgia, otorrhea, aural fullness, any chronic systemic disease such as anemia, or hyperthyroidism. Having ototoxicity, head and neck trauma history, continuous drug use, or smoking were also the criteria of exclusion from the study group. The patients had no otologic intervention history and their hearing acuity was not affected. The examinations of head and neck were unremarkable, and no auscultable bruit over the mastoid was detected. The control group was formed by the retrospective evaluation of the reconstructed images of the petrous bones derived from the paranasal CT scans of 35 patients performed because of chronic sinusitis. The patients in the control group had no ear pathology or tinnitus.

The temporal bones of 35 patients with SPT were assessed with a Somatom Sensation 16 CT (Siemens AG, Erlangen, Germany). The CT acquisition parameters were as follows: tube current, 150 mAs; voltage, 120 kV; detector collimation, 16x0.75; rotation time, 0.4 second; table speed, 1 mm/rotation (pitch, 0.92); slice thickness, 1 mm; scan time, 1.26 s; field of view (FOV), 250; and matrix, 512x512.

## Statistical Analysis

Mean, standard deviation, proportion, and frequency were calculated. The distribution of the outcome was evaluated with the Kolmogorov-Smirnov test. The independent-samples t test was used for comparison of the means between two groups. For analysis of proportional data, the chi-square ( $\chi^2$ ) test was used. SPSS 20.0 (IBM Corp.; Armonk, NY, USA) was used for the analyses.

## Results

Overall, 19 (54.28%) of the 35 patients included in the study group were male and the remaining 16 (45.71%) were female. The mean age was  $48.2 \pm 12.5$  years. In the control group, 18 (51.42%) of the 35 patients were male and 17 (48.57%) were female. The mean age was  $47.6 \pm 13.2$  years. There was no statistically significant difference between the study and control groups in terms of age or gender ( $p > 0.05$ ). In the study group, unilateral tinnitus was observed in 24 patients (68.57%) and bilateral tinnitus was observed in 11 patients (31.42%). Overall, 46 ears with SPT were evaluated. Of these 46, 13 (28.26%) had petrous bone pneumatization, and of the 13, 11 had increased pneumatization formed of small aircells and two had predominant large aircells between internal carotid artery (ICA) and cochlea (Figure 1, 2). The control group consisted of 35 patients (70 ears) with no ear complaints. Unilateral pneumatization was noted in seven patients and bilateral pneumatization in four patients. In the control group, 15 (21.42%) of 70 ears had petrous bone pneumatization. On comparing study and control groups, no

significant relationship was found between petrous pneumatization and tinnitus ( $p > 0.05$ ).

## Discussion

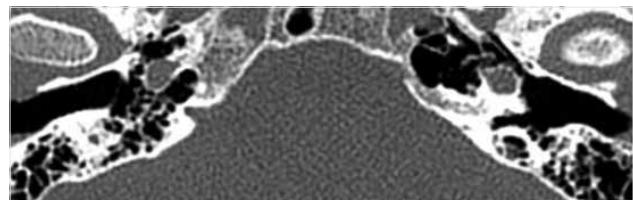
Different studies reveal that in the general population, there are no majorly different ratios in the incidence of petrous apex pneumatization. A study conducted by Glick et al. (14) reveals that pneumatization was found in 12 (29%) of 42 temporal bones. Lindsay et al. (15) detected petrous apex pneumatization at a ratio of 21% in their series of 100 temporal bones. Jen et al. (16) found this ratio to be 33% in their study, and Virapongse et al. (17) detected this ratio to be 35% in 141 patients.

The mechanism of PT is explained as the transmission of the sound of turbulent blood flow arising from a vessel to the inner ear (3). Local or systemic disorders affecting hemodynamics may lead to a non-laminar blood flow in major vessels such as ICA. It is speculated that in the case of increased resonance, the enhanced transmission of the normal sounds without any non-laminar blood flow may also lead to SPT (9). Large air cells between ICA and cochlea may serve as an amplifier and as a result by enhancing the transmission of the normal blood flow sounds to cochlea can lead to PT (18).

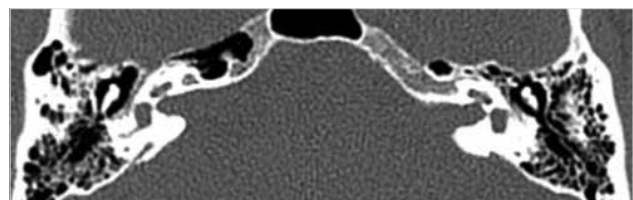
Topal et al. (19) presented an increased aeration of the temporal bone in two patients. Yao et al. (20) demonstrated a case with unilateral SPT in which the CT scan revealed the erosion of the bone between the cochlear basal turn and ICA. Their case shows that abnormal run of ICA may result in the transmission of regular vibrations of the arterial wall to perilymph or endolymph, thus causing SPT.

A study conducted by Tüz et al. (21) presents the case of a patient with SPT that had diffuse pneumatization in the temporal bone around ICA, and they related the late onset of tinnitus to decreased insulation around the ICA because of osteoporosis in the bone as a result of old age.

A study by Xue et al. (22) suggests that focal defects at the sigmoid and transverse junctions of the mastoid bone cause PT because tinnitus completely regresses after the reconstruction of the bone. Lund et al. (23) demonstrated a patient with PT due to carotid artery-cochlear dehiscence diagnosed by CT.



**Figure 1.** Petrous pneumatization formed of mainly unilocular large aircell at the left side



**Figure 2.** Petrous pneumatization formed of mainly unilocular large aircell at the right side

Remembering the physics law that sound waves are better conducted in solids compared with air, in cases of pneumatization where bone is exchanged with air cells, we should not expect amplification in the conduction of the normal blood flow sound. In our study, we did not find any significant relationship between pneumatization and tinnitus, but we detected two cases of patients with bilateral pneumatization, who had SPT at the side of pneumatization, which mainly consisted of a unibody large air cell; however, the opposite sides, which consisted of multiple small air cells, were free of tinnitus. For these cases, a question arises whether combination of thin bony lamellas and tiny air cells together cause multiple interfaces resulting in dispersion and reflection thus reducing the energy of the sound and existence of a unibody large air cell conducting the sound with relatively less distortion and thus resulting in not amplification but less interference on the sound can be perceived by cochlea as relatively increased conduction of the blood flow and result in SPT. To prove this theory, a study with a large number of cases in resemblance needs to be conducted.

Radiological evaluations will reveal no abnormality in most of the patients to explain the cause of their tinnitus. The main aim of the imaging study of a patient with tinnitus is to demonstrate the treatable causes. We tried to share our experience on imaging of SPT.

## Conclusion

Tinnitus can be the first finding of a wide variety of diseases with life-threatening pathologies. It is very important to relate radiological findings to patient symptoms before concluding that this finding is responsible for tinnitus. In our study, no significant relationship was found between petrous pneumatization and tinnitus. According to our experience, the coexistence of SPT with large air cells between ICA and cochlea may be an answer to some of the unexplained causes of tinnitus. To prove this theory, a study with large number of cases in resemblance has to be conducted.

**Ethics Committee Approval:** Ethics committee approval was received for this study from the ethics committee of Şişli Hamidiye Etfal Education and Research Hospital.

**Informed Consent:** Informed consent is not obtained due to the retrospective nature of this study.

**Peer-review:** Externally peer-reviewed.

**Author Contributions:** Concept - A.S.M.; Design - A.S.M.; Supervision - A.S.M., İ.Ç.; Resource - A.S.M.; Materials - A.S.M., İ.Ç.; Data Collection and/or Processing - A.S.M., İ.Ç.; Analysis and/or Interpretation - A.S.M., İ.Ç.; Literature Search - A.S.M.; Writing - A.S.M., İ.Ç.; Critical Reviews - A.S.M., İ.Ç.

**Conflict of Interest:** No conflict of interest was declared by the authors.

**Financial Disclosure:** The authors declared that this study has received no financial support.

**Etik Komite Onayı:** Bu çalışma için etik komite onayı Şişli Hamidiye Etfal Eğitim ve Araştırma Hastanesi Etik Kurul Komitesinden alınmıştır.

**Hasta Onamı:** Bu çalışma retrospektif veriler kullanılarak yapıldığından hasta onamı alınmamıştır.

**Hakem Değerlendirmesi:** Dış Bağımsız.

**Yazar Katkıları:** Fikir - A.S.M.; Tasarım - A.S.M.; Denetleme - A.S.M., İ.Ç.; Kaynaklar - A.S.M.; Malzemeler - A.S.M., İ.Ç.; Veri Toplanması ve/veya İşlemesi - A.S.M., İ.Ç.; Analiz ve/veya Yorum - A.S.M., İ.Ç.; Literatür taraması - A.S.M.; Yazıyı Yazan - A.S.M., İ.Ç.; Eleştirel İnceleme - A.S.M., İ.Ç.

**Çıkar Çatışması:** Yazarlar çıkar çatışması bildirmemiştir.

**Finansal Destek:** Yazarlar bu çalışma için finansal destek almadıklarını beyan etmişlerdir.

## References

- Bauer CA. Mechanisms of tinnitus generation. *Curr Opin Otolaryngol Head Neck Surg* 2004; 12: 413-7. [\[CrossRef\]](#)
- Axelsson A, Ringdahl A. Tinnitus a study of its prevalence and characteristics. *Br J Audiol* 1989; 23: 53-62. [\[CrossRef\]](#)
- Adams PF, Hendeshot GE, Marano MA; Centers for Disease Control and Prevention/National Center for Health Statistics. Current estimates from the National Health Interview Survey, 1996. *Vital Health Stat* 1999; 200: 1-203.
- Lockwood AH, Burkard RF, Salvi RJ. Imaging tinnitus. Snow JB, editor. *Tinnitus: theory and management*. Hamilton: Decker; 2004.p.255-64.
- Weissman JL. Imaging of Meniere's disease. *Otolaryngol Clin North Am* 1997; 30: 1105-16.
- Shiley SG, Folmer RL, McMenomey SO. Tinnitus and hyperacusis. Cummings CW, editor. *Otolaryngology: head and neck surgery*. Philadelphia: Elsevier; 2005.p.2832-47.
- Dietz RR, Davis WL, Harnsberger HR, Jacobs JM, Blatter DD. MR imaging and MR angiography in the evaluation of pulsatile tinnitus. *AJNR Am J Neuroradiol* 1994; 15: 879-89.
- Weissman JL, Hirsch BE. Imaging of tinnitus: a review. *Radiology* 2000; 216: 342-9. [\[CrossRef\]](#)
- Luxon LM. Tinnitus: its causes, diagnosis, and treatment. *BMJ* 1993; 306: 1490-1. [\[CrossRef\]](#)
- Marsot-Dupuch K. Pulsatile and nonpulsatile tinnitus: a systemic approach. *Semin Ultrasound CT MRI* 2001; 22: 250-70. [\[CrossRef\]](#)
- Branstetter BF 4th, Weissman JL. The radiologic evaluation of tinnitus. *Eur Radiol* 2006; 16: 2792-802. [\[CrossRef\]](#)
- Olsen WL, Dillon WP, Kelly WM, Norman D, Brant-Zawadzki M, Newton TH. MR imaging of paragangliomas. *AJR Am J Roentgenol* 1987; 148: 201-4. [\[CrossRef\]](#)
- Alataki S, Koulouris G, Stuckey S. CT-demonstrated transcalvarial channels diagnostic of dural arteriovenous fistula. *AJNR Am J Neuroradiol* 2005; 26: 2393-6.
- Glick HN. Microscopic observation of the petrous apex. *Ann Otol Rhinol Laryngol* 1933; 42: 175-91. [\[CrossRef\]](#)
- Lindsay JR. Petrous pyramid of temporal bone: pneumatization and roentgenologic appearance. *Arch Otolaryngol* 1940; 31: 231-55. [\[CrossRef\]](#)
- Jen A, Sanelli PC, Banthia V, Victor JD, Selesnick SH. Relationship of petrous temporal bone pneumatization to the eustachian tube lumen. *Laryngoscope* 2004; 114: 656-60. [\[CrossRef\]](#)
- Virapongse C, Sarwar M, Bhimani S, Sasaki C, Shapiro R. Computed tomography of temporal bone pneumatization: 1. Normal pattern and morphology. *Am J Roentgenol* 1985; 145: 473-81. [\[CrossRef\]](#)
- Branstetter BF, Weissman JL. The radiologic evaluation of tinnitus. *Eur Radiol* 2006; 16: 2792-802. [\[CrossRef\]](#)
- Topal O, Erbek SS, Erbek S, Ozuoglu LN. Subjective pulsatile tinnitus associated with extensive pneumatization of temporal bone. *Eur Arch Otorhinolaryngol* 2008; 265: 123-5. [\[CrossRef\]](#)
- Yao W, Benjamin LC, Korzec K. Aberrant internal carotid artery causing erosion of the otic capsule: an unusual cause of pulsatile tinnitus. *Otolaryngol Head Neck Surg* 1998; 118: 678-9. [\[CrossRef\]](#)
- Tüz M, Doğru H, Yeşildağ A. Subjective pulsatile tinnitus associated with extensive pneumatization of temporal bone. *Auris Nasus Larynx* 2003; 30: 183-5. [\[CrossRef\]](#)
- Xue J, Li T, Sun X, Liu, Y. Focal defect of mastoid bone shell in the region of the transverse-sigmoid junction: a new cause of pulsatile tinnitus. *J Laryngol Otol* 2012; 126: 409-13. [\[CrossRef\]](#)
- Lund AD, Palacios SD. Carotid artery-cochlear dehiscence: a review. *Laryngoscope* 2011; 121: 2658-60. [\[CrossRef\]](#)

**Cite this article as: Mahmutoğlu AS, Çelebi İ. Can the configuration of petrous bone pneumatization be a predictor of tinnitus? Istanbul Med J 2018; 19: 22-4.**