



Hemangioma Originating from the Soft Palate

Yumuşak Damaktan Köken Alan Hemangioma

Erdiñ Aydın¹, Kübra Çoban²

Hemangiomas are benign proliferative vascular malformations characterized by hyperplasia of venous and capillary structures embedded in the submucosal connective tissue. In adults, hemangiomas are rare lesions, and 50% patients are aged >40 years. Most hemangiomas are observed in the head and neck region; however, the oral cavity is a rare location. The soft palate is one of the rarest locations in the oral cavity for hemangiomas. In this report, a large cavernous hemangioma in the soft palate of male adult is presented. Literature review and current diagnostic and treatment modalities are discussed.

Keywords: Hemangioma, soft palate, oral cavity tumors

Hemangiomlar, benign proliferatif vasküler malformasyonlardır. Submukozal bağ doku içerisindeki venlerin ve kapiller damarların hiperplazisi ile karakterizedir. Erişkinlerde nadir görülmektedir ve erişkin hastaların %50'si 40 yaş üzerindedir. Vakaların çoğu, baş ve boyun bölgesinde izlenmektedir, ancak oral kavite, bu bölgedeki en nadir lokalizasyonlardan biridir. Burada, yumuşak damakta büyük kavernöz hemangiom tanılı erkek erişkin hasta sunulmuştur. Böylelikle, bu patolojiye yönelik literatür gözden geçirilmiş, güncel tanı ve tedavi yöntemleri tartışılmıştır.

Anahtar Kelimeler: Hemanjiom, yumuşak damak, oral kavite tümörleri

Introduction

Hemangiomas are benign proliferative vascular malformations characterized by abnormal expansion of veins and capillaries settled in the submucosal connective tissue. They are barely encapsulated (1). They appear in a younger population and represent the most common head and neck neoplasm at the pediatric age, occurring in 5%-10% children aged <1 year (2). In adults, hemangiomas are rare lesions, and 50% patients are aged >40 years (2). Generally, 60%-70% of hemangiomas are observed in the head and neck; however, the oral cavity is still an uncommon location for a hemangioma (1). They may be observed in any area of the oral cavity, such as the tongue, buccal mucosa, lips, gingiva, but they are rarely observed in the hard and soft palate (2, 3). They can be extremely small or large unpleasant tumors (3). Spontaneous remission is unlikely during adulthood (4). There is a higher prevalence in females (3:1-7:1). We present the case of a 33-year-old male diagnosed with a large cavernous hemangioma in the soft palate. We reviewed the literature and discussed current diagnostic and treatment measures.

Case Report

A 33-years-old Caucasian, otherwise healthy, male visited Başkent University Medical Faculty Otorhinolaryngology Department with a mass on his palate. He had realized this mass a couple of years ago when he was undergoing a checkup before his military duty. He had once experienced a massive hemorrhage of the mass and an uvulectomy had been performed as a treatment at a different health center. No pathological diagnosis was obtained previously. The patient had no comorbid systemic diseases and had no trauma history to the palate. His otorhinolaryngological examination unremarkable except a blue color, soft, pulsatile 5×3-cm mass originating from the left soft palatal region and extending to the left tonsillar area and hard palate (Figure 1). His routine laboratory tests and urine analysis were in the normal range. During nasopharyngeal examination, an anastomosis of large vessels, which was organized as a vascular mass, was detected. Computed tomography (CT) showed a mass arising from the posterior of the soft palate and obstructing the airway passage in the nasopharyngeal area, in which calcified areas were observed. After intravenous contrast injection, homogenous contrast enhancement was observed. According to magnetic resonance imaging (MRI), the mass was hypointense in T1-weighted images and hyperintense in T2-weighted images (Figure 2). Multiple septations were observed in the mass, but invasion to the surrounding tissue was not detected. These radiological findings strongly indicated a hemangioma.

¹Department of Otorhinolaryngology, Başkent University School of Medicine Ankara Hospital, Ankara, Turkey

²Department of Otorhinolaryngology, Başkent University Alanya Research Hospital, Antalya, Turkey

Address for Correspondence

Yazışma Adresi:

Kübra Çoban

E-mail: kubracob81@gmail.com

Received/Geliş Tarihi: 21.02.2017

Accepted/Kabul Tarihi: 22.04.2017

© Copyright 2017 by Available online at
www.istanbulmedicaljournal.org

© Telif Hakkı 2017 Makale metnine
www.istanbultipdergisi.org web sayfasından
ulaşılabilir.

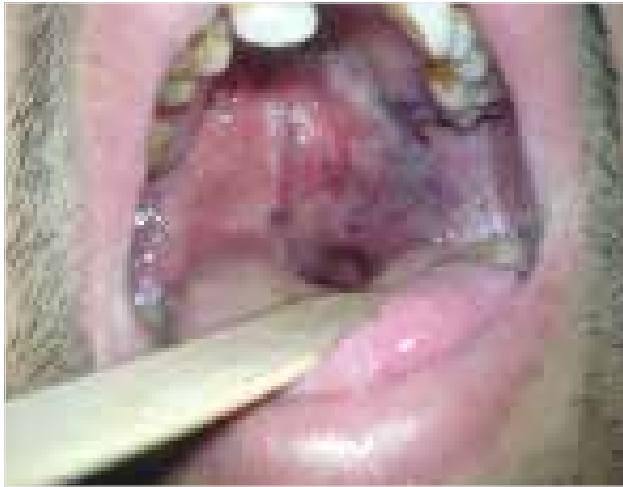

Figure 1. Intraoral view of the lesion in the left palatal region

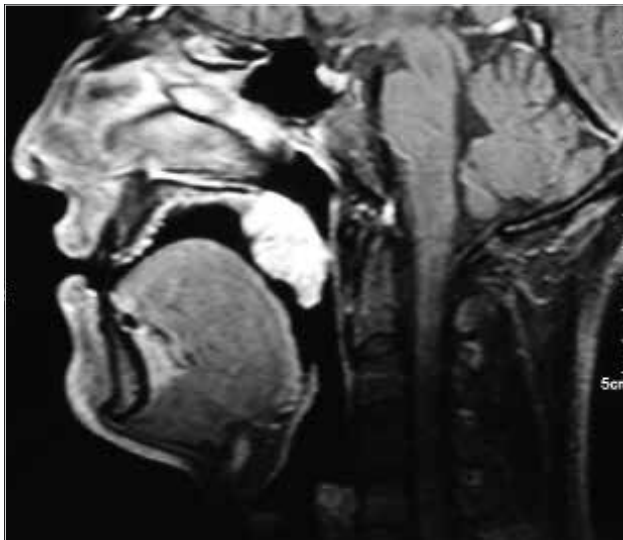


Figure 2. Neck MRI sagittal scanning of the patient. The lesion is visible with contrast enhancement

The patient was radiological findings were explained in detail, and he was referred to angiography for detecting vascular supply and embolization. In the radiology department, the patient underwent angiography through the Seldinger technique. According to this, a femoral catheter was introduced and a guide wire was inserted. This wire then passed up the common iliac artery, descending aorta, into the common carotid artery, and finally into the external carotid artery. As determined by the image intensifier, the catheter passed over the guide wire and contrast medium was injected to observe the vascular supply of the lesion.

During this evaluation, it was observed that the lesion was predominantly supplied by the left facial artery. The lobular nature of the mass and its angiographical appearance supported the diagnosis of hemangioma. A sclerosing agent was then introduced into the lesion, and the procedure was completed without any complications. During the follow-up, the mass was observed to decrease in size. Embolization was repeated once again afterwards. MRI was repeated during the 3rd and 5th year of follow-up. The lesion did not significantly decrease in size. Surgical excision was suggested although the patient refused.

Informed consent was obtained from the participant.

Discussion

Hemangiomas are benign vascular tumors composed of newly formed vessels (4-6). They are classified into three major groups: capillary, cavernous, and mixed (1, 3, 5, 6). According to its depth and soft tissue involvement, they can be further classified as superficial, deep, and mixed (3). Capillary hemangiomas consist of small capillaries, lined by single-layer endothelial cells, settled in a connective tissue. Cavernous hemangioma, however, is characterized by widely dilated thin-walled vessels or sinuses, which are separated by connective tissue stroma (1).

Hemangiomas are soft, smooth, or lobulated; painless; sessile or pedunculated; pink to red purple lesions that blanch when pressure is exerted (1). They are commonly observed in females (1) and 50% of the cases are over 40 years of age (2) are relatively rare. Our case was of a male aged 33 years. The mass was soft, smooth, sessile, and red purple in color, similar to those described in literature (1, 2). Hemorrhage may result spontaneously or following trauma. The patient had one previous experience of spontaneous bleeding of the lesion. Hemangiomas, located particularly in the soft palate, as in this case, are very infrequently observed.

Radiographic imaging is recommended in selective cases. CT and MRI are useful for analyzing exact features of the lesion, such as the size, location, extension, and relation with surrounding vital structures. They are also used for differential diagnosis and for follow-up of lesions treated using non-surgical measures (1).

Contrast-enhanced CT is an effective imaging technique, but sometimes hemangiomas are enhanced insufficiently; thus, distinguishing lesions from the surrounding tissues may be difficult (5). MRI is superior to CT for evaluating soft tissue masses. The accurate delineation of the tumor is demonstrated using MRI (5). In MRI, these tumors typically show low-signal intensity on T1-weighted images and high-signal intensity on T2-weighted images (5). Septations can be detected within the lesion on T2-weighted images visualized as low-intensity structures. Focal areas of low-signal intensity indicate phleboliths on both T1- and T2-weighted images.

Angiographically, hemangiomas are well-circumscribed lesions demonstrating intense tissue staining organized in a lobular pattern (7). This technique shows afferent and efferent vascular supply of hemangiomas. In addition, low-flow lesions may be distinguished from high-flow lesions, such as arteriovenous malformations (7). Moreover, angiography provides a therapeutic effect on these lesions. In our case, angiography demonstrated that the mass was predominantly supplied by the left facial artery.

This patient was evaluated using CT, MRI, and angiography. The diagnosis of hemangioma was supported with clinical findings and radioangiographical imaging. Accordingly, with regard to its diagnosis, large size, and location, surgery was not the first treatment option. Embolization was considered.

Most of the hemangiomas may need no interventions. However, various factors are considered for their management. The watch and wait policy, intralesional or systemic corticosteroid therapies, embolization techniques, excision, immunomodulatory therapies,

and laser photocoagulation are the most popular therapies (1, 4). Sclerotherapy is favored because of its efficiency and ability to secure the surrounding structures (1). Indications for surgery are no evidence for involution, very large tumors with or without thrombocytopenia, involvement of the adjacent structures, symptomatic (hemorrhage and infection) tumors, or cosmetic risk (1, 4, 7).

During the 5 years of follow-up, with two sclerotherapy interventions, the mass neither regressed nor progressed. The patient was free of any related complaints. He refused to undergo surgery, and he is still under close follow-up.

Conclusion

Although hemangiomas are frequently observed in the head and neck region, the soft palate is considered an infrequent locus among other head and neck surfaces. In addition, instances of hemangiomas in males are very rare in literature. Although hemangiomas are benign in nature and has conservative treatment options, because of its size, location, and wide vascular supply, unpleasant conditions such as hemorrhage, infection, or impingement to vital structures may occur. A close follow-up and exact differential diagnosis from other benign oral cavity tumors are essential. Treatment modalities, in our opinion, should be patient specific. Thus, the most appropriate and applicable therapy for the patient should be decided.

Informed Consent: Written informed consent was obtained from the patient who participated in this study.

Peer-review: Externally peer-reviewed.

Author contributions: Concept - E.A.; Design - E.A., K.C.; Supervision - E.A.; Resource - E.A., K.C.; Materials - E.A., K.C.; Data Collection and/or Processing - E.A., K.C.; Analysis and/or Interpretation - E.A., K.C.; Literature Search - K.C.; Writing - K.C.; Critical Reviews - E.A.

Conflict of Interest: No conflict of interest was declared by the authors.

Financial Disclosure: The authors declared that this study has received no financial support.

Hasta Onamı: Yazılı hasta onamı bu çalışmaya katılan hastadan alınmıştır.

Hakem Değerlendirmesi: Dış Bağımsız.

Yazar Katkıları: Fikir - E.A.; Tasarım - E.A., K.C.; Denetleme - E.A.; Kaynaklar - E.A., K.C.; Malzemeler - E.A., K.C.; Veri Toplanması ve/veya İşlemesi - E.A., K.C.; Analiz ve/veya Yorum - E.A., K.C.; Literatür taraması - K.C.; Yazıyı Yazan - K.C.; Eleştirel İnceleme - E.A.

Çıkar Çatışması: Yazarlar çıkar çatışması bildirmemişlerdir.

Finansal Destek: Yazarlar bu çalışma için finansal destek almadıklarını beyan etmişlerdir.

References

1. Kamala KA, Ashok L, Sujatha GP. Cavernous hemangioma of the tongue: A rare case report. *Contemp Clin Dent* 2014; 5: 95-8. [\[CrossRef\]](#)
2. Singh P, Parihar AS, Siddique SN, Khare P. Capillary haemangioma on the palate: a diagnostic conundrum. *BMJ Case Rep* 2016; 16: 2016. [\[CrossRef\]](#)
3. V P, Puppala N, Deshmukh SN, B J, S A. Cavernous hemangioma of tongue: management of two cases. *J Clin Diagn Res* 2014; 8: 15-7. [\[CrossRef\]](#)
4. Kornfehl J, Gstöttner W, Kontrus M, Sedivy R. Transpalatine excision of a cavernous hemangioma of the infratemporal fossa. *Eur Arch Otorhinolaryngol* 1996; 253: 172-5. [\[CrossRef\]](#)
5. Yonetsu K, Nakayama E, Miwa K, Tanaka T, Araki K, Kanda S, et.al. Magnetic resonance imaging of oral and maxillofacial angiomas. *Oral Surg Oral Med Oral Pathol* 1993; 76: 783-9. [\[CrossRef\]](#)
6. Itoh K, Nishimura K, Togashi K, Fujisawa I, Nakano Y, Itoh H, et al. MR imaging of cavernous hemangioma of the face and neck. *J Comput Assist Tomogr* 1986; 10: 831-5. [\[CrossRef\]](#)
7. Watzinger F, Gössweiner S, Wagner A, Richling B, Millesi-Schobel G, Holmann K. Extensive facial vascular malformations and haemangiomas: a review of the literature and case reports. *J Craniomaxillofac Surg* 1997; 25: 335-43. [\[CrossRef\]](#)

Cite this article as: Aydın E, Çoban K. Hemangioma Originating from the Soft Palate. *İstanbul Med J* 2017; 18: 239-41.