



# Oral Propranolol Administration in Treatment of Hemangiomas: An Update

## Hemanjiom Tedavisinde Oral Propranolol Kullanımı Sonuçlarımız: Güncelleme

Rahşan Özcan<sup>1</sup>, Sevil Aktemur<sup>1</sup>, Şenol Emre<sup>1</sup>, İbrahim Adaletli<sup>2</sup>, Ergun Erdoğan<sup>1</sup>, Gonca Topuzlu Tekant<sup>1</sup>

Abstract / Öz

**Objective:** To evaluate the results and the efficacy of oral propranolol treatment in patients with infantile hemangioma.

**Methods:** The records of the patients, who received oral propranolol treatment in our clinic between 2009 and 2015, were retrospectively investigated. The patients were evaluated according to age, gender, lesion localization, propranolol indication, age at the beginning of treatment, complications, side effects, and treatment outcome.

**Results:** The mean age of the 30 enrolled patients (22 females and 8 males) was 13.6 months (2 months-10 years). The indications for propranolol use were hemangiomas, presented with a life-threatening condition, local complications, or unpleasant cosmetic appearance. In 10 patients (33%), treatment was started at the age of 0-6 months, in 17 patients (57%) at the age of 6-12 months, and in 3 patients (10%) at the age of 1 year and older. Fourteen (46.7%) patients fully responded to treatment, while 11 (36.7%) showed a partial response. Five (16.7%) patients did not respond to treatment.

The mean duration of the propranolol use in non-responders (n=5) was 6.4 months (2-9 months).

There was a statistically significant difference between the treatment response and the duration of propranolol use. There was no significant difference between the age at the beginning of the treatment and the response to the treatment.

**Conclusion:** Propranolol treatment is a safe and effective method for the management of infantile hemangioma. It may be administered as the first-line treatment, as well as in relapsing patients.

**Keywords:** Hemangiomas, propranolol, recurrence

**Amaç:** Infantil hemanjiom olgularında kullanılan oral propranolol tedavisi sonuçlarının ve etkinliğinin değerlendirilmesidir.

**Yöntemler:** 2009-2015 yıllarında propranolol tedavisi alan olguların kayıtları geriye dönük olarak incelendi. Olgular yaş, cins, lezyon lokalizasyonu, propranolol kullanım endikasyonu, tedaviye başlama yaşı, komplikasyonlar, yan etkiler ve tedavi sonuçlarına göre değerlendirildi.

**Bulgular:** Otuz olgunun (K: 22,E: 8) yaş ortalaması 13.6 ay (2 ay-10 yaş) idi. Propranolol kullanım endikasyonları; yaşam tehdidi, lokal komplikasyon yada kötü kozmetik görünümdü. Tedaviye başlama yaşı olguların 10'unda(%33) 0-6 ay, 17'sinde (%57) 6-12 ay, 3'ünde (%10) 1 yaş ve üstü olarak saptandı. Tedavi değerlendirilmesinde olguların 14'ünde (%46,7) tam yanıt, 11'inde(%36,7) kısmi yanıt saptandı. Beşi (%16,7) tedavisiye yanıtızsıdı.

Tedaviye yanıtızsı 5 olguda propranolol 6,4 ay (2-9 ay) kullanıldı. Bu olgulara tekrar yapılan radyolojik ve klinik değerlendirmede 2 olgunun lenfanjiom ile uyumlu olduğu izlendi ve 1'ine bleomisin enjeksiyonu yapıldı, diğeri takip edilmektedir. Geri kalan 3 olgunun birine dış merkezde cerrahi eksizyon yapıldı. Birine alkol enjeksiyonu uygulandı. 1 olgu takip edilmektedir.

Tedavi yanıtları ve ilaç kullanım süreleri arasında istatistiksel olarak anlamlı fark bulundu. Tedaviye başlama yaşı ile yanıt arasında anlamlı fark saptanmadı.

**Sonuç:** Hemanjiom tedavisinde propranolol kullanımı güvenilir ve etkili bir yöntemdir. İlk tedavi seçeneği olarak kullanılabilceği gibi nüks olgularda da kullanılabilir. Tedaviye yanıtızsı olgularda mutlaka tekrar radyolojik değerlendirme yapılmalıdır. Tedavi süresi ilaca yanıtı değiştirmektedir.

**Anahtar Kelimeler:** Hemanjiom, propranolol, rekürrens

## Introduction

The incidence of infantile hemangioma (IH) ranges between 2% and 10% (1-3). It is one of the most common childhood tumors. Most of the IHs that emerge in the first 2 weeks after birth regress spontaneously before the age of 4-7 years (4). However, 10%-12% of the patients require treatment due to complications. Propranolol, a beta-blocker, has been used since 2008 in the hemangioma treatment (2, 5). There are several studies reporting that oral propranolol is an effective and safe treatment modality, especially in the first year after birth, which is the proliferative phase of hemangioma.

The aim of our study was to evaluate the results and the efficacy of oral propranolol treatment in IH.

## Material and Methods

The records of the patients who were diagnosed with IH at our clinic and received oral propranolol treatment between 2009 and 2015 were retrospectively reviewed.

<sup>1</sup>Department of Pediatric Surgery, İstanbul University Cerrahpaşa School of Medicine, İstanbul, Turkey

<sup>2</sup>Department of Radiology, İstanbul University Cerrahpaşa School of Medicine, İstanbul, Turkey

Address for Correspondence  
Yazışma Adresi:  
Rahşan Özcan  
E-mail: rozcan1@gmail.com

Received/Geliş Tarihi: 17.05.2017

Accepted/Kabul Tarihi: 22.05.2017

© Copyright 2017 by Available online at  
www.istanbulmedicaljournal.org

© Telif Hakkı 2017 Makale metnine  
www.istanbulmedj.org web sayfasından ulaşılabilir.

The patients were evaluated with respect to age, gender, localization of the lesion, indication for propranolol use, age at the beginning of the treatment, treatment outcome, side effects, and complications. The indications for the initiation of the propranolol treatment were life-threatening conditions, local complications, or unpleasant cosmetic appearance. Before the propranolol treatment, full blood count and blood glucose levels were examined in all the patients. Routine cardiological examination, electrocardiography, and echocardiography were carried out. Patients with normal blood findings and cardiological examination were included in the study. Radiological imaging was done with ultrasound (USG). Magnetic resonance imaging of the lesions located in the head and neck area, in the midline, and in suspected patients was also performed.

The patients were hospitalized before the propranolol treatment. The initial dosage of 0.5 mg/kg/day was administered in 2 divided doses. Cardiac parameters and blood pressure were monitored closely, and blood glucose levels were checked 4 times a day. In patients who had normal values of all the monitored parameters, the dose was increased to 2 mg/kg/day, and the patients were discharged on the second day of the treatment. The first control in the outpatient clinic was done after 15 days. The parents were advised to take a picture of the lesion, measure the blood pressure and the pulse once a week, and check the blood glucose level twice a week.

The response to propranolol treatment was evaluated according to the changes in the color and size of the lesion and radiological examination. A 75% decrease in the size and a significant change in color of the lesion were assessed as a "full response," a 50%-75% decrease in the size and fading in color were assessed as a "partial response," and no significant change was labeled as "non-response." Following the treatment, the propranolol application was discontinued after a gradual dose decrease.

Ethics committee approval was received for this study from the ethics committee of Cerrahpasa Medical Faculty. Informed consent was not received because the study was made retrospectively by examining file records of the patients after ethic committee approval.

Mann-Whitney U-test and Chi-Squared test were used for statistical analysis. Statistical significance level of alpha was accepted as  $p < 0,05$ . Data analysis was conducted using Statistical Package for Social Sciences software version 15.0 (SPSS Inc.; Chicago, IL, USA).

**Results**

The mean age of the 30 included patients (22 females and 8 males) was 13.6 months (2 months-10 years). The following are lesion locations: head and neck (n=13), perineal-gluteal area (n=7), trunk (n=5), and intraabdominal area (n=1) (Figure 1). Seven patients had more than one hemangioma with different localizations. Indications for the propranolol administration were unpleasant cosmetic appearance (n=17), local complications (ulceration, infection, postsurgical relapse; n=8) and life-threatening conditions (hemorrhage [n=3] and respiratory distress [n=2]). All of the lesions were initially interpreted as hemangioma after the radiological examination. In 10 patients, the age at the start of the treatment was 0-6 months (33%), in 17 patients, 6-12 months (57%), and in 3 patients, it was 1 year and older (10%) (Table 1).

Considering the treatment evaluation, 14 patients had a full response (46.7%), 11 patients a partial response (36.7%), and 5 patients had no response (16.7%) (Table 2).

The age at the beginning of the treatment was 13.3 months (2-96 months) in patients with a full response (n=14), 16.5 months (2-120 months) in patients with a partial response, and 8.4 months (5-12 months) in patients with no response (n=5).

There was no statistically significant difference between the age at the beginning of treatment and the response to the propranolol treatment ( $p > 0.05$ ).

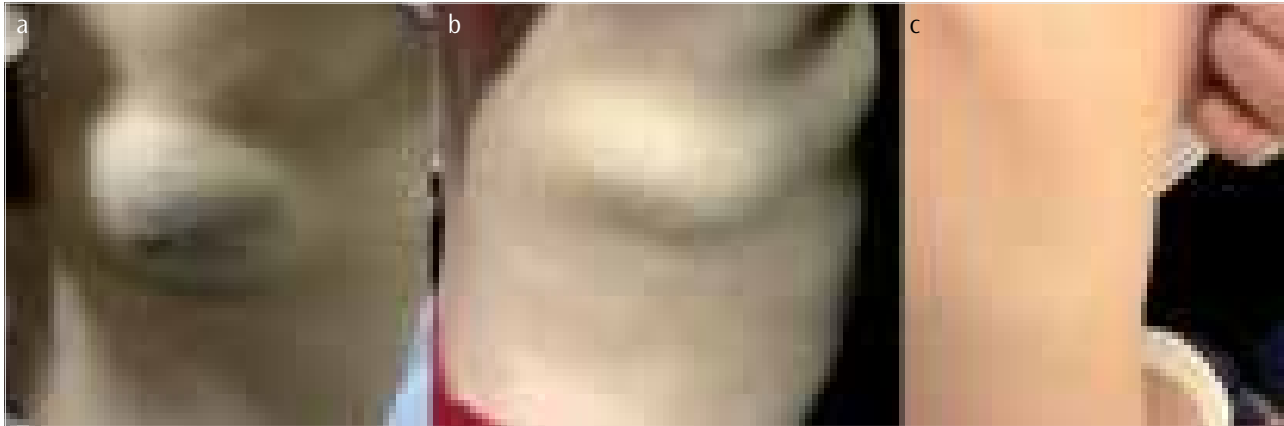
The propranolol application lasted 14.3 months (2-24 months) in patients with a full response (n=14), 8.1 months (3-24 months) in patients with a partial response (n=11), and 6.4 months (2-9 months) in patients with no response (n=5).

**Table 1. Demographic characteristics of the patients**

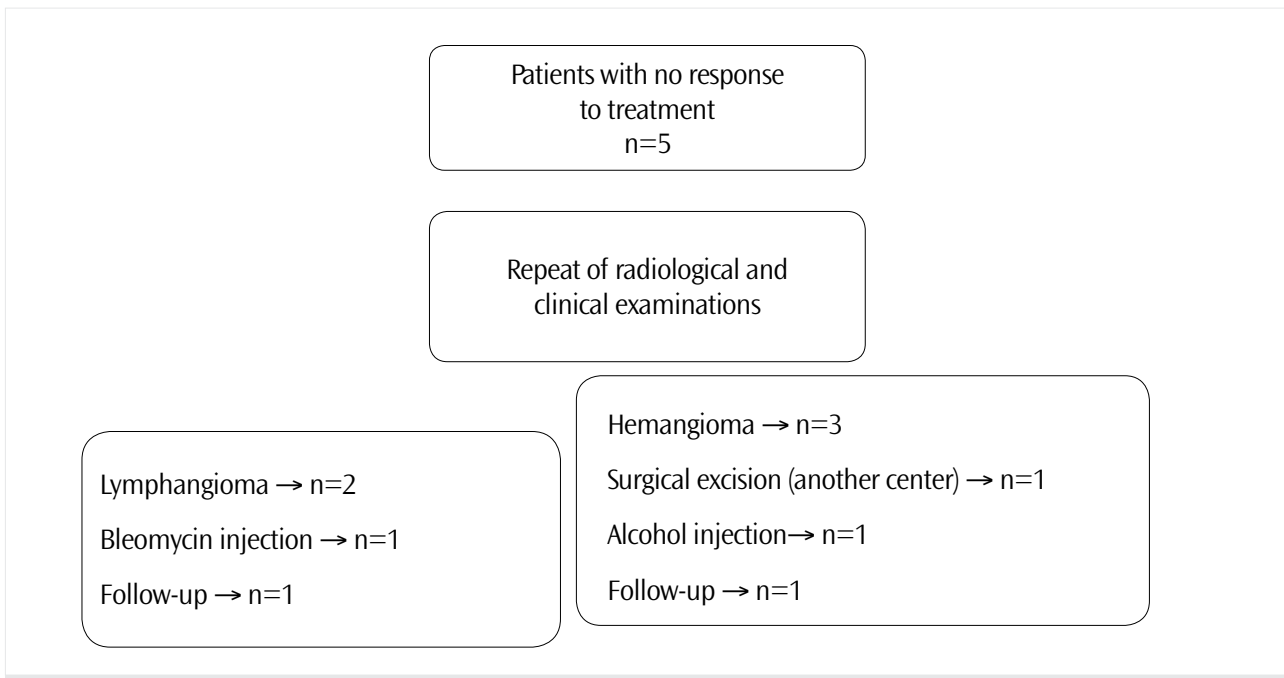
Number of patients (n)	30
Mean age	13.6 months (R: 2 months-10 years)
Females/Males	22/8
<b>Location of the lesions (n)</b>	
- Head and neck	13
- Extremities	12
- Perineal-gluteal	7
- Trunk	5
- Intraabdominal	1
<b>Indication for the propranolol use (n)</b>	
- Unpleasant cosmetic appearance	17
- Local complications	8
- Ulceration, infection	7
- Postsurgical relapse	1
- Life-threatening conditions	5
- Hemorrhage	3
- Respiratory distress	2
<b>Side effects (n)</b>	
- Hypoglycemia	1

**Table 2. Comparison of the response to the treatment with the age at the beginning of propranolol treatment and the duration of propranolol treatment ( $p < 0.05$  was accepted as statistically significant)**

Response to the Treatment	Number of Patients (n)	Age at the Start of the Treatment (months)	Duration of Propranolol Use (months)
Full response	14	13.3 (2-96)	14.3 (2-24)
Partial response	11	16.5(2-120)	8.1 (3-24)
No response	5	8.4 (5-12)	6.4 (2-9)
p		0.717	0.040*



**Figure 1. a-c.** A 3.5-year-old female patient, with hemangioma of the right scapular region (a) before the treatment; (b) 6 months after the propranolol treatment; and (c) 18 months after the propranolol treatment



**Figure 2.** Results of the evaluation of patients with no response

There was a statistically significant difference between the duration of the propranolol use and the response to the treatment ( $p < 0.05$ ).

The mean follow-up period after the discontinuation of the drug was 28.5 months (3-48 months) in patients with a full response ( $n=14$ ) and 24.1 months (0.5-48 months) in patients with a partial response ( $n=11$ ).

The repeated clinical and radiological examination in 5 patients who did not respond to the propranolol treatment revealed that 2 of them had lymphangioma. One of them received bleomycin injection, and the other one is still under follow-up. One patient underwent surgical excision in another medical center, and the pathological examination indicated hemangioma. One patient received alcohol injection, and the other patient is under follow-up (Figure 2).

Hypoglycemia occurred only in 1 patient during the propranolol treatment. No other side effects were observed.

## Discussion

Infantile hemangiomas are known as benign vascular tumors that are rather common in childhood. IHs usually emerge within the first few weeks after birth. A fast proliferation phase is followed by stabilization and regression phases. IHs are tumors that regress spontaneously and disappear between the ages of 4 and 7, even without any treatment. However, 10%-15% of patients require treatment due to the various complications (4, 6). Common indications for the treatment are certain risks, which may cause problems, such as functional and cosmetic problems with regard to localization, local complications (e.g., ulceration and bleeding and obstruction according to the localization), and life-threatening conditions such as respiratory distress (7). In our study, the most common indications for the treatment were lesions with unpleasant cosmetic appearance and local complications such as bleeding and ulceration.

Several medical methods (e.g., systemic steroids, interferon, and vincristine) have been recommended for IH treatment. Oral pro-

pranolol treatment was introduced by Léauté-Labrèze in 2008 (5, 8). The goal of propranolol treatment is to decrease the growth during the proliferation phase and to induce regression. Therefore, related studies suggested the use of propranolol in the fast progression phase, that is, during the first year after birth (2, 6). In 90% of the patients in our study, the propranolol treatment was initiated before the age of 1. However, there was no statistically significant difference between the age at the beginning of the propranolol treatment and the response to the treatment.

With regard to literature, almost all the studies focused on the propranolol treatment were retrospective studies. As there are only a few prospective, randomized studies, there is no consensus on routine cardiological examination before the IH treatment and on the propranolol dose. In most of the studies, routine cardiological examination and ECG were recommended. On the other hand, as the co-occurrence of IH and cardiac anomaly has not been reported, routine echocardiography has not been recommended (9). However, we consider routine cardiological examination before the treatment and ECG and echocardiography as necessary for all the patients. We did not find any patients with cardiac anomaly in our patient group.

The recommended propranolol dose in the literature is 1-3 mg/kg/day. The common view is that the propranolol treatment should be started with a low dose, which should be increased until the target dose is reached, monitoring at the same time the cardiac effects and blood glucose levels (10, 11). In our clinic, we begin propranolol treatment with a starting dose of 0.5 mg/kg/day after the patient hospitalization. The targeted dose is 2 mg/kg/day.

The most common side effects of the propranolol treatment are hypotension, bradycardia, and hypoglycemia (12). Bronchoconstriction, diarrhea, gastroesophageal reflux, and acrocyanosis are less frequently encountered. Although the cause of hypoglycemia remains unclear, glycogenolysis and gluconeogenesis induced by catecholamines and the inhibition of lipolysis may be responsible. In different patient groups, there were only a few propranolol side effects reported, and it was stated that propranolol was an effective and safe IH treatment method. In the meta-analysis of Léauté-Labrèze et al. (9), it was reported that propranolol treatment did not cause any serious side effects and that it might be safely used. Moodley (13) reported in his study that they did not observe any side effect. In our patient group, we did not encounter any side effects except hypoglycemia in 1 patient.

In published studies, there is no consensus on the duration of propranolol treatment. Chang et al. conducted a study with 149 patients and reported that the appropriate therapy should be continued until a response was obtained or until 1 year of age. In the same study, it was also stated that the duration of the treatment was longer and the recurrence rate was higher in patients with partial response (2). In other studies, it was also emphasized that the recurrence rates were ranging between 10% and 30% in patients with early treatment discontinuation (2, 10). In our study, there was also a statistically significant difference between the duration of propranolol treatment and the response to the treatment. Therefore, we believe that propranolol should be applied for at least 1 year in case of IH, and the decision about the discontinuation should be made according to the clinical and radiological data.

It was reported that the rate of IH patients, who did not respond to propranolol treatment, was 2% to 10% (13). The same rate was 16.7% in our patient group. The reason for this conflicting result is that 2 patients were erroneously diagnosed with hemangioma after the first radiological examination. The re-evaluation showed that the lesions in these patients were lymphangiomas, and they were treated accordingly. In the remaining 3 patients, the duration of the propranolol treatment was shorter compared to the patients with a full and partial response. We believe that this affected the treatment non-responsiveness.

## Conclusion

Propranolol use is an effective and safe method in IH treatment, and it can be considered the first-line therapy. It was observed that the clinical response continued during the prolonged administration of the drug. In patients with no response to treatment, clinical and radiological evaluation should be repeated. In IH patients with no response to propranolol, other treatment options should be considered.

**Ethics Committee Approval:** Ethics committee approval was received for this study from the ethics committee of Cerrahpaşa Medical Faculty.

**Informed Consent:** Informed consent was not obtained due to the retrospective nature of the study.

**Peer-review:** Externally peer-reviewed.

**Author contributions:** Concept - R.Ö., G.T.T.; Design - Ş.E., E.E.; Supervision - R.Ö., S.A., G.T.T.; Resource - R.Ö., S.A., Ş.E.; Data Collection and/or Processing - S.A., R.Ö., İ.A.; Analysis and/or Interpretation - R.Ö., G.T.T., E.E.; Literature Search - R.Ö., Ş.E.; Writing - R.Ö., İ.A., G.T.T.; Critical Reviews - G.T.T., R.Ö.

**Conflict of Interest:** No conflict of interest was declared by the authors.

**Financial Disclosure:** The authors declared that this study has received no financial support.

**Etik Komite Onayı:** Bu çalışma için etik komite onayı Cerrahpaşa Tıp Fakültesi Etik Komitesi'nden alınmıştır.

**Hasta Onamı:** Çalışmanın retrospektif doğası nedeniyle hasta onamı alınmamıştır.

**Hakem Değerlendirmesi:** Dış Bağlımsız.

**Yazar Katkıları:** Fikir - R.Ö., G.T.T.; Tasarım - Ş.E., E.E.; Denetleme - R.Ö., S.A., G.T.T.; Kaynaklar - R.Ö., S.A., Ş.E.; Veri Toplanması ve/veya işleme - S.A., R.Ö., İ.A.; Analiz ve/veya Yorum - R.Ö., G.T.T., E.E.; Literatür taraması - R.Ö., Ş.E.; Yazıyı Yazan - R.Ö., İ.A., G.T.T.; Eleştirel İnceleme - G.T.T., R.Ö.

**Çıkar Çatışması:** Yazarlar çıkar çatışması bildirmemişlerdir.

**Finansal Destek:** Yazarlar bu çalışma için finansal destek almadıklarını beyan etmişlerdir.

## References

- Dong JY, Ning JX, Li K, Liu C, Wang XX, Li RH, et al. Analysis of factors affecting the therapeutic effect of propranolol for infantile haemangioma of the head and neck. *Sci Rep* 2017; 7: 342. [CrossRef]

2. Chang L, Gu Y, Yu Z, Ying H, Qiu Y, Ma G, et al. When to stop propranolol for infantile hemangioma. *Sci Rep* 2017; 7: 43292-9. [\[CrossRef\]](#)
3. Dilek M, Bekdaş M, Gökşügür SB, Demircioğlu F, Karataş Z, Erkoçoğlu M, et al. Infantile hemangioma and oral propranolol therapy. *The Medical Bulletin of Şişli Etfal Hospital* 2015; 49: 148-51. [\[CrossRef\]](#)
4. Karaca İ, Türk E, Meşe T, Demirağ B, Faytoncu Ş. The use of propranolol as first-line treatment of infantile hemangioma: Case presentation. *İzmir Dr. Behçet Uz Çocuk Hast Derg* 2014; 4: 65-8. [\[CrossRef\]](#)
5. Léauté-Labrèze C, Dumas de la Roque E, Hubiche T, Boralevi F, Thambo JB, Taïeb A. Propranolol for severe hemangiomas of infancy. *N Engl J Med* 2008; 358: 2649-51. [\[CrossRef\]](#)
6. Phillips RJ, Crock CM, Penington AJ, Bekhor PS. Prolonged tumour growth after treatment of infantile haemangioma with propranolol. *Med J Aust* 2017; 206: 131. [\[CrossRef\]](#)
7. Smithson SL, Rademaker M, Adams S, Bade S, Bekhor P, Davidson S, et al. Consensus statement for the treatment of infantile haemangiomas with propranolol. *Australas J Dermatol* 2017; 58: 155-9. [\[CrossRef\]](#)
8. Léauté-Labrèze C, Harper JI, Hoeger PH. Infantile haemangioma. *Lancet* 2017; 390: 85-94. [\[CrossRef\]](#)
9. Léauté-Labrèze C, Boccard O, Degrugillier-Chopin C, Mazereeuw-Hautier J, Prey S, Lebbé G, et al. Safety of Oral Propranolol for the Treatment of Infantile Hemangioma: A Systematic Review. *Pediatrics* 2016 ;138: 1-21. [\[CrossRef\]](#)
10. Rotter A, Samorano LP, de Oliveira Labinas GH, Alvarenga JG, Rivitti-Machado MC, et al. Ultrasonography as an objective tool for assessment of infantile hemangioma treatment with propranolol. *Int J Dermatol* 2017; 56: 190-4. [\[CrossRef\]](#)
11. Neckman JP, Geronemus RG. Commentary on Moodley S et al. "Shouldn't Propranolol be Used to Treat All Hemangiomas?" and Dr. Blei's Invited Commentary. *Aesthetic Plast Surg* 2016; 40: 327-8. [\[CrossRef\]](#)
12. Xiao Q, Li Q, Zhang B, Yu W. Propranolol therapy of infantile hemangiomas: efficacy, adverse effects, and recurrence. *Pediatr Surg Int* 2013; 29: 575-81 [\[CrossRef\]](#)
13. Moodley ST, Hudson DA, Adams S, Adams KG. Shouldn't Propranolol Be Used to Treat All Haemangiomas? *Aesth Plast Surg* 2015; 39: 963-7. [\[CrossRef\]](#)

**Cite this article as: Özcan R, Aktemur S, Emre Ş, Adaletli İ, Erdoğan E, Topuzlu Tekant G. Oral Propranolol Administration in Treatment of Hemangiomas: An Update. *İstanbul Med J* 2017; 18: 227-231.**