



B-Mode Gray Scale Histogram Value in Diagnosis of Adolescent Patients with Hashimoto Thyroiditis

Hashimoto Tiroiditli adölesan Hastalarının tanısında B-Mod Gri Skala Histogramın Değeri

Bülent Çekiç¹, İlhan Nahit Mutlu², Ayşe Eda Parlak¹, Yasemin Köksel¹, İclal Erdem Toslak¹, Mesut Parlak³

Abstract / Öz

Introduction: The most common type of autoimmune thyroiditis is Hashimoto thyroiditis (HT), which is the leading cause of hypothyroidism. Although ultrasound examination aids in the diagnosis of the disease, it does not have a specific quantitative value. The aim of this study was to evaluate the parenchymal echogenicity alterations of the thyroid gland in adolescent patients with HT using B-mode gray scale histogram and to reveal the predictive value of this technique in the diagnosis of HT.

Methods: A total of 76 patients with HT and 46 healthy controls were prospectively examined by the gray scale histogram analysis method. The analysis included the thyroid echogenicity/strap muscle echogenicity ratio (TESER) and thyroid stimulating hormone (TSH), anti-thyroid peroxidase (anti-TPO), anti-thyroglobulin (anti-TG).

Results: The mean TESER that was significantly lower in the HT group compared to the control group (1.36 ± 0.46 vs 2.24 ± 0.59 ; $p < 0.01$). There was a negative correlation between anti-TPO level and TESER in the correlation analysis ($r = -0.426$, $p < 0.01$). The optimal cut-off value of TESER for the prediction of HT was < 1.59 (72% sensitivity, 93% specificity, +likelihood ratio: 11, -LR: 0.30).

Conclusion: Ultrasonographic gray scale histogram values can be used as an auxiliary ultrasound parameter in the diagnosis and follow-up of HT in adolescent patients.

Keywords: Gray scale histogram, hashimoto thyroiditis, adolescent

Amaç: Hashimoto Tiroiditi (HT), Otoimmün tiroiditlerin en sık görülen tipi olup hipotiroidinin başlıca sebebidir. Tiroid ultrason incelemesi HT tanısında yardımcı bir yöntem olup kantitatif bir değer vermemektedir. Bu çalışmamızın amacı HT tanılı adölesan hastalarda B-mod gri skala histogram yöntemini kullanarak tiroid parankim ekojenitesi değişikliklerini tesbit etmek ve HT tanısında prediktif değerini ortaya koymaktır.

Yöntemler: 76 HT tanılı ve 46 adölesan dönem kontrol grubuna prospektif olarak, tiroid bezinin B-mod gri skala histogram analizi ve Tiroid stimulan Hormon (TSH) tetkikleri, antitiroid peroksidaz (anti-TPO) ve antitiroglobülin (anti-TG) otoantiklorları tetkikleri yapıldı. Gri skala histogram analizi yapmak için Tiroid ekojenite/strap kası ekojenite oranı (TESER) kullanıldı.

Bulgular: Ortalama Tiroid ekojenite/strap kası ekojenite oranı (TESER) HT'li grupta $1,36 \pm 0,46$, kontrol grubunda ise $2,24 \pm 0,59$ olup istatistiksel olarak anlamlı olarak daha düşüktü ($p < 0,01$). Anti-TPO seviyeleri ile TESER arasında pearson korelasyon analizinde negatif korelasyon mevcuttu ($r = -0,426$, $p < 0,01$). TESER'in HT tanısında prediktif optimal cut-off değeri $< 1,59$ (72% sensitivite, 93% spesifite) olarak bulduk.

Sonuç: Ultrasonografik Gri Skala Histogram yöntemi adölesan dönemde HT tanısında ve takibinde, noninvaziv kolay uygulanabilen yardımcı bir parametre olarak kullanılabileceğini inanmaktayız.

Anahtar Kelimeler: Gri skala histogram, hashimoto tiroidit, adölesan

Introduction

Hashimoto thyroiditis (HT) is the most common type of the autoimmune and inflammatory disease of the thyroid gland. Euthyroid pediatric patients comprise 55%-65% of the HT population, which is the leading cause of the subsequent hypothyroidism (1-3).

In patients with HT, lymphocytic infiltration occurs in the thyroid gland parenchyma leading to gradual decrease in thyroid gland echogenicity on ultrasonography (US) examinations by the time. The association between the inflammatory changes of the thyroid gland parenchyma and the serum level of anti-thyroid peroxidase (anti-TPO) and anti-thyroglobulin (anti-TG) autoantibodies is well known (4). The diagnosis of the HT depends on increased serum autoantibodies (anti-TPO and anti-TG) and thyroid US in daily clinical practice (3). The B-mode parameters used for diagnosis and follow-up of HT include thyroid gland volume, hypoechogenicity, and gland echogenicity heterogeneity alterations. Currently, the alterations in echogenicity are performed by subjective eyeballing and are thus operator dependent (5, 6). Therefore, there is a need for a quantitative measurement of the degree of echogenicity of the thyroid gland in adolescent patients with HT.

The aim of this study was to evaluate the parenchymal echogenicity alterations of the thyroid gland in adolescent patients with HT using B-mode gray scale histogram and to reveal the predictive value of this technique in the diagnosis of this entity.

¹Department of Radiology, Antalya Training and Research Hospital, Antalya, Turkey

²Department of Radiology, Istanbul Training and Research Hospital, Istanbul, Turkey

³Department of Pediatric Endocrinology, Antalya Training and Research Hospital, Antalya, Turkey

Address for Correspondence

Yazışma Adresi:

Bülent Çekiç

E-mail: bulend71@yahoo.com

Received/Geliş Tarihi: 06.03.2017

Accepted/Kabul Tarihi: 21.05.2017

© Copyright 2017 by Available online at
www.istanbulmedicaljournal.org

© Telif Hakkı 2017 Makale metnine
www.istanbultipdergisi.org web sayfasından
ulaşılabilir.

Material and Methods

Study design

All procedures were followed in accordance with the ethical standards of the responsible committee on human experimentation (institutional and national) and with the Helsinki Declaration of 1975, as revised in 2008. The ethics committee approval for this research was given by the ethics committee at Antalya Training and Research Hospital. Informed consent was obtained from patients and control group patients included in the study.

A total of 80 cases diagnosed with HT in the Pediatric Endocrinology Department between May 05, 2015, and May 05, 2016, were prospectively recruited for the study. The patients were selected by the pediatric endocrinologist per their clinical and laboratory parameters, and those meeting the criteria for euthyroid autoimmune thyroiditis and without medications for at least 6 months were included in the study. Patients with prior surgery or biopsy, parenchymal nodule, and calcification or cystic lesion were excluded from the study. Overall, 4 of 80 patients were excluded for various reasons (2 with thyroidal nodule and 2 with parenchymal calcification). A control group was formed of 47 adolescents who were referred to the Radiology Department after presentation at the Pediatric Endocrinology Department with no evidence of thyroid disease. One of the control subjects was excluded as parenchymal nodule was determined. The remaining control individuals were proven to be devoid of any thyroid disorder based clinical, laboratory, or US findings.

Clinical and laboratory features

The clinical diagnosis of HT was based on the increased levels of anti-TPO (normal range: 0-10 IU/mL) and/or anti-TG (normal range: 0-4 IU/mL). Since hyperthyroidism, hypothyroidism, and euthyroidism are from different sub-groups, the results (degree of thyroid echogenicity) could have been affected. Therefore, only euthyroid patients were included and this was defined as thyroid stimulating hormone (TSH) and free thyroxine (fT4) within the normal reference range (TSH: 0,36-5,8 IU/mL, fT4: 0,61-1,12 ng/dL). Serological assays were performed in the same week along with the US evaluation. All the blood samples were stored at the room temperature for at least 30 min to allow clotting, followed by centrifugation (2500 rpm) for 15 min at 4°C to separate sera. Hormonal parameters were assayed immediately. Additional serum was isolated from fasting blood samples and stored at -80°C prior to analysis of TSH, fT4, anti-TPO, and anti-TG, which were determined using a two-site immunoenzymatic method with a commercially available kit and autoanalyzer (Beckman DxI800; Beckman Coulter Diagnostics, CA, USA). The intra- and inter-assay coefficients of variation for the assays were <10%.

Ultrasound imaging

All patients were scanned using a Hitachi Hi-Vision Preirus (Tokyo, Japan) US device equipped with a 7-13 MHz linear-array broadband probe. Patients were lying supine with the neck overextended. All examinations were performed by the same radiologist (B.C.). The radiologist was blinded to the diagnosis. The thyroid glands of the patients were evaluated in terms of size, echogenicity, and nodules on B-mode US. Subsequently, B-mode histogram examinations were performed.

Gray scale histogram analysis

To provide standardization of the histogram measurements, specific B-mode parameters were selected; Time Gain Compensation values were -30 to 30 dB, and all patients were scanned in the mid (0 dB) level. B-mode gain levels were between 0 and 60, and the gain was adjusted to level 40. The focus-level interval was from 0 to 3 and focus of level 1.5 was used. The longitudinal and axial US images of the thyroid gland were recorded in the database in a JPEG format and transferred to a separate workstation. The Image J software (National Institutes of Health, MD, USA) was used for gray scale histogram analysis of the images. The largest possible ROI (8×8 mm in size) was drawn to evaluate the largest possible thyroid gland echogenicity. A second ROI was drawn manually on the strap muscles as the reference value within the same image (Figure 1). The quantitative histogram measurements of both thyroid lobes and the strap muscles were carried out and averages were calculated.

Echogenicity values were measured as 0-255 (0: black, 255: white) using the histogram analysis in a sampling area. The parenchyma echogenicity ratio was defined as the ratio between the echogenicity value of the thyroid parenchyma to the echogenicity value of the strap muscles (thyroid echogenicity/strap muscle echogenicity ratio [TESER]; Figure 2 and 3).

Statistical analysis

All data in the study were analyzed using the Statistical Package for Social Sciences for Windows 10.0 software (SPSS Inc; Chicago, IL, USA) The Mann-Whitney U test was used to compare differences between two independent groups. The Fisher's exact test was applied to non-parametric data and the Pearson correlation test was used for correlation analysis. A p value of <0.05 was considered statistically significant. The Kolmogorov-Smirnov test was used to determine the distribution of the data. If the data followed a normal distribution, values were presented as mean±standard deviation (SD), and the Student t-test was applied to analyze the data. For parameters that followed non-normal distribution, values were stated as median in a 95% confidence interval and were analyzed using the Mann-Whitney U test. The Spearman test was applied for correlation analysis. To differentiate the HT group and the control group, different predictive models were compared using receiver-operating characteristic-area under curve (ROC-AUC) statistics. For different predictive models, AUC, cut-off points, sensitivity, specificity, positive predictive value (+PV), negative predictive value (-PV), positive likelihood ratio (+LR), and negative likelihood ratio (-LR) values were determined. Data were expressed as mean±SD or median (interquartile range), as appropriate. All differences associated with a chance probability of 0.05 or less were considered statistically significant. The AUC values near to 1,0 represented perfect test results; values of <0.05 were equivalent or worse results than expected by random chance. The AUC values had the following interpretation: 0.9-0.99=excellent test; 0.8-0.89=good test; 0.7-0.79=fair or reasonable test; and 0.51-0.69=poor test.

Results

A prospective examination was conducted for 76 patients, comprising 18 (24%) males and 58 (76%) females) with HT and 46 healthy control subjects comprising 10 (22%) males and 36 (78%) females. The median values of age, BMI (kg/m²) TSH (mIU/L), and fT4 (ng/dL) values were 14,7 years (14-15,5), 20,7 (20,3-22,3), 2,4 (1,9-2,7),

Table 1. Comparisons of the values between HT and control groups

Variables	Patient (n=76)	Control (n=46)	p
Age (years)	14.7 (14-15,5)	15.6 (15-16)	0.07
Gender (female)	58 (76%)	36 (78%)	0.99
BMI (kg/m ²)	20.7 (20,3-22,3)	20.9 (19,4-23)	0.76
TSH (mIU/L)	2.4 (1,9-2,7)	1.85 (1,6-2,2)	0.28
ft4 (ng/dl)	0.80 (0,80-0,81)	0.80 (0,78-0,87)	0.81
Anti-TG (IU/ml)	7.3 (2,25-25,8)	0.3 (0,2-0,7)	<0.01
Anti-TPO (IU/ml)	267 (190-476)	0.5 (0,3-0,6)	<0.01
TESER	1.36±0.46	2.24±0.59	<0.01

HT=Hashimoto thyroiditis, BMI=body mass index, TSH=thyroid stimulating hormone, ft4=free thyroxine, anti-TG=anti-thyroglobulin, anti-TPO=anti-thyroid peroxidase, TESER=thyroid echogenicity/strap muscle echogenicity ratio

Table 2. Estimates of diagnostic tests for the HT and control group for the differentiation of the echogenicity method (TESER)

	AUC	Cut-off	Sensitivity (%)	Specificity (%)	+LR	-LR
TESER	0.890	<1.59	72	93	11	0.30

HT: hashimoto thyroiditis; +PV: positive predictive value; -PV: negative predictive value; +LR: positive likelihood ratio; -LR: negative likelihood ratio; AUC: area under curve; TESER: thyroid echogenicity/strap muscle echogenicity ratio

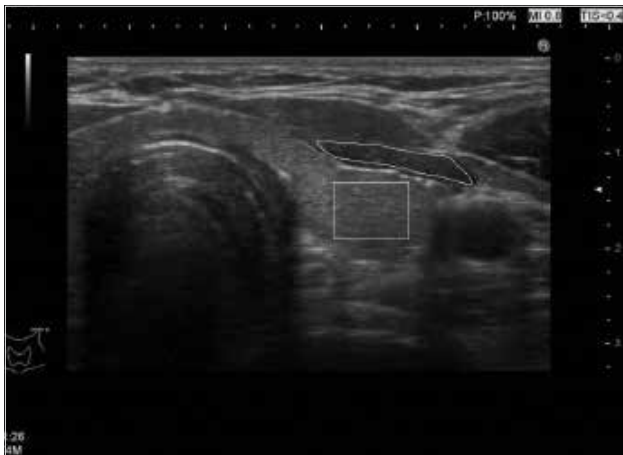

Figure 1. Axial US gray scale image of thyroid parenchyma. Big rectangular ROI on the thyroid parenchyma and a one manually drawn ROI on the strap muscle were set to cover the largest possible target tissue

and 0,80 (0,80-0,81), respectively, in the patient group and 15,6 years (15-16), 20,9 (19,4-23), 1,85 (1,6-2,2), and 0,80 (0,78-0,87), respectively, in the control group. No significant difference was determined between the two groups in terms of age, gender, BMI, TSH, and ft4 (p=0,07, 0,99, 0,76, 0,28, 0,81, respectively, Table 1).

The mean anti-TG values (normal range: 0-4 IU/mL) were 7,3 IU/ml (2,25-25,8) in the HT group and 0,3 IU/ml (0,2-0,7) in the control group. The mean anti-TPO values of the HT and control group were (normal range: 0-10 IU/mL) 267 IU/ml (190-476) and 0,5 IU/ml (0,3-0,6), respectively. The mean anti-TG and anti-TPO values were significantly higher in the HT group (Table 1). There was a negative correlation between anti-TPO level and TESER in the correlation analysis (r=-0,426, p<0,01; Figure 4).

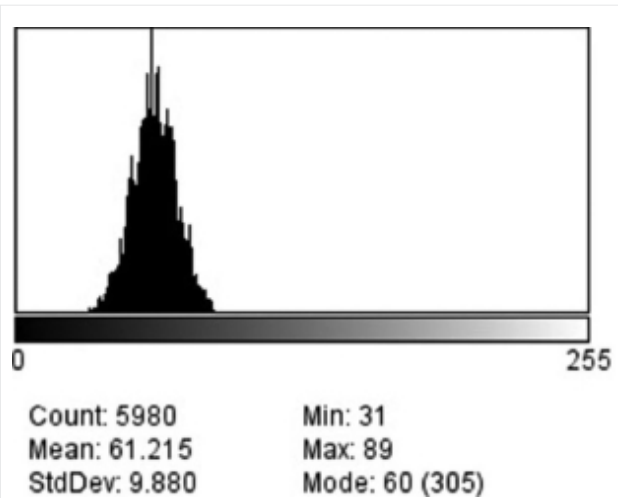


Figure 2. Histogram analysis shows the distribution of the intensity of pixels of thyroid parenchyma. Mean, standard deviation, and mode are shown below

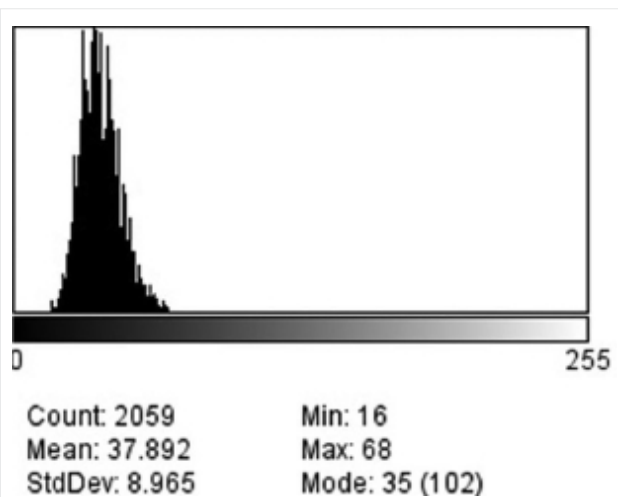


Figure 3. Histogram analysis shows the distribution of the intensity of pixels of strap muscle. Mean, standard deviation, and mode are shown below

The mean TESER was significantly lower in the HT group at 1,36±0,46 than that in the control group at 2,24±0,59 (p<0,01). The optimal cut-off value of TESER for the prediction of HT was <1,59 (72% sensitivity, 93% specificity, +LR: 11, -LR: 0,30). The AUC value was 0,890 (Table 2; Figure 5).

Discussion

In this study, the feasibility of gray scale histogram US was evaluated in the diagnosis of HT in adolescent patients. The TESER values obtained using the gray scale histogram method in this study were significantly lower in HT group than those in control group. Also, the gray scale histogram US method was shown to have 93% specificity in diagnosing HT. In the light of these results, we propose that gray scale histogram method can be used as a non-invasive, quantitative complimentary method to US in the diagnosis and follow-up of the adolescent patients with HT.

In HT, the thyroid gland parenchyma undergoes both histological and structural changes, including lymphocytic infiltration, de-

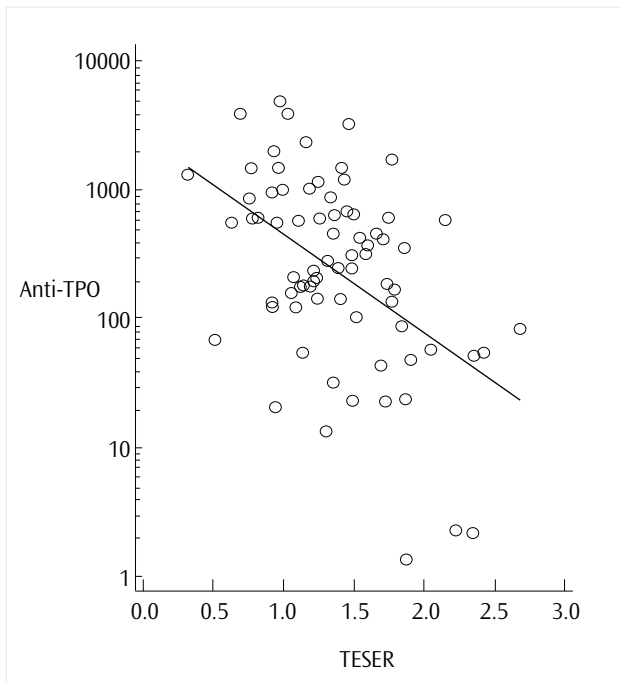


Figure 4. In the correlation analysis, there was a negative correlation between anti-TPO and the echogenicity ratio (TESER; $r=-0.426$; $p<0.01$).

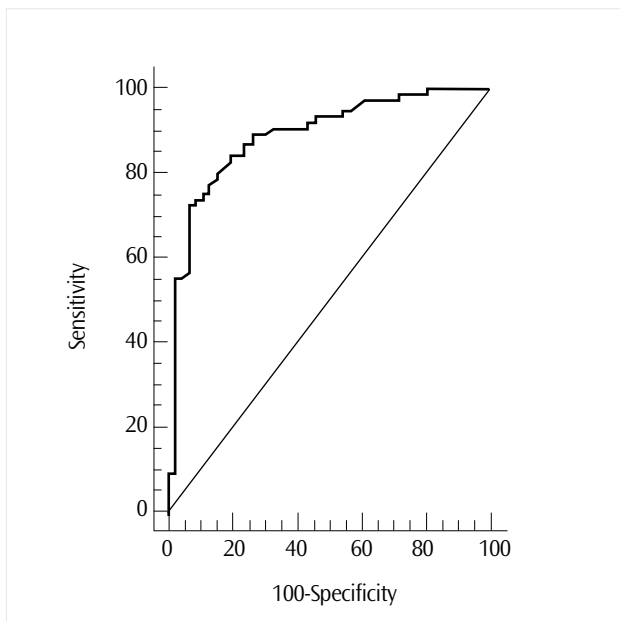


Figure 5. ROC curve of echogenicity (TESER); area under curve was 0,890, and the optimal cut-off value was 1.59

increased colloidal content, fibrosis, increased intra-thyroidal blood flow, and follicular structural distortion. These aforementioned histopathological changes cause a decrease in the thyroid gland parenchymal echogenicity and heterogeneous gland upon US examinations (7, 8).

Hypoechoogenicity of thyroid gland echogenicity is determined by observing the adjacent neck muscles (sternocleidomastoid or strap muscles) as reference organs (9). However, this type of evaluation is operator dependent and it may result in variability in the definition of hypoechoogenicity of the thyroid gland depending on the operator differences. Furthermore, the term hypoechoogenicity is a

qualitative definition, and it does not provide quantitative information about the degree of echogenicity (10, 11).

The gray scale histogram analysis provides objective and quantitative information regarding thyroid parenchymal echogenicity (8). US images have a spectrum of gray scale histogram values. Each pixel in these US images reflects a different color density. The histogram method reveals the corresponding mean distribution of the color density for each pixel and shows this information as a graphic. Consequently, US images can be reflected as a numerical value and as a quantitative measure through the gray scale histogram method (12).

There are few studies in the literature concerning the diagnosis of thyroid gland diseases using the gray scale histogram analysis method. In those studies, hypoechoogenicity values were calculated by obtaining the mean thyroid parenchymal pixel values (9, 13-16). Maziotti et al. (15) evaluated the thyroid gland parenchymal echogenicity of 89 patients with a diagnosis of HT (44 hypothyroidism patients, 45 euthyroid individuals) and 40 healthy controls. The mean thyroid echogenicity values in the HT group was $61,9\pm 8,3$ and significantly lower than those in the control group that had a mean thyroid echogenicity value of $71,2\pm 3,1$ ($p=0,01$). Schiemanm et al. (9) studied 52 HT patients with subclinical thyroiditis who were taking medications and 100 healthy controls. They found significantly lower thyroid parenchymal echogenicity values in the HT group. They also found a relationship between the increased thyroid gland hypoechoogenicity and increased TSH and anti-TPO values. Loy et al. (13) conducted a study with 77 patients diagnosed with HT (28 with euthyroidism, 20 with subclinical hypothyroidism, and 29 with symptomatic hypothyroidism). Out the 29 patients, 6 were not under medical treatment and 23 were under L-thyroxin treatment. They showed a significant relationship between the L-thyroxin treatment and decreased thyroid gland hypoechoogenicity.

It is a well known fact that there is a relationship between thyroid parenchymal echogenicity differences and increased TPO antibodies in patients with goiter, particularly in those with increased TSH values (i.e., subclinical hypothyroidism patients) (9). In the current study, all patients were in euthyroid state and their TSH levels were within normal limits. Besides, potential thyroid gland parenchymal echogenicity variations were eliminated by including only adolescent patients into the study population. Furthermore, to eliminate both operator- and patient-related thyroid gland parenchymal echogenicity differences, we defined strap muscles as a reference tissue and obtained a ratio by dividing thyroid gland parenchymal histogram values to strap muscles histogram values (TESER ratio). Loy et al. and Maziotti et al. (13, 15) could not find a significant correlation between thyroid gland parenchymal echogenicity histogram values and anti-TPO values. In the current study, we did find a negative correlation between anti-TPO and TESER values (Figure 4). Increased anti-TPO values reflect lymphocyte infiltration within the thyroid gland, which is one of the leading causes of the decreased echogenicity (hypoechoogenicity) of the thyroid gland.

Our study has several limitations. Although there was a correlation between the lymphocytic infiltration and anti-TPO values, the study lacked a histopathological evaluation of the patients, since tissue sampling is not routinely applied to adolescent patients with a presumed diagnosis of thyroiditis in our institution.

Another limitation of our study was the small sample size. Further studies with a larger number of patients would further enhance the study results with increased statistical power.

Conclusion

The gray scale histogram method can quantitatively differentiate normal and heterogeneous thyroid gland parenchyma in adolescent patients with HT. TESER values obtained by dividing thyroid gland parenchymal histogram values to strap muscles histogram values negatively correlate with anti-TPO values. We suggest the use of this auxiliary tool as an adjunct to the conventional B-mode US for the diagnosis and follow-up of adolescent patients with HT.

Ethics Committee Approval: The ethics committee approval was received for this study from the ethics committee at Antalya Training and Research Hospital.

Informed Consent: Informed consent was obtained from the patients and control group who participated in this study.

Peer-review: Externally peer-reviewed.

Author contributions: Concept - B.Ç., M.P., Y.K.; Design - İ.E.T., B.Ç.; Supervision - İ.N.M.; Resource - Y.K.; Materials - M.P.; Data Collection and/or Processing - İ.N.M., İ.E.T.; Analysis and/or Interpretation - B.Ç., M.P.; Literature Search - A.E.P., Y.K.; Writing - B.Ç.; Critical Reviews - İ.E.T.

Conflict of Interest: No conflict of interest declared by the authors.

Financial Disclosure: The authors declared that this study has received no financial support.

Etik Komite Onayı: Bu çalışma için etik komite onayı Antalya Eğitim ve Araştırma hastanesi Etik Kurulu'ndan alınmıştır.

Hasta Onamı: Hasta onamı bu çalışmaya katılan hastalardan alınmıştır.

Hakem Değerlendirmesi: Dış Bağlıdır.

Yazar Katkıları: Fikir - B.Ç., M.P., Y.K.; Tasarım - İ.E.T., B.Ç.; Denetleme - İ.N.M.; Kaynaklar - Y.K.; Malzemeler - M.P.; Veri Toplanması ve/veya İşlemesi - B.Ç., M.P.; Analiz ve/veya Yorum - İ.N.M., İ.E.T.; Literatür taraması - A.E.P., Y.K.; Yazıyı Yazan - B.Ç.; Eleştirel İnceleme - İ.E.T.

Çıkar Çatışması: Yazarlar çıkar çatışması bildirmemişlerdir.

Finansal Destek: Yazarlar bu çalışma için finansal destek almadıklarını beyan etmişlerdir.

References

1. Hamburger JI. The various presentations of thyroiditis Diagnostic considerations. *Ann Intern Med* 1986; 104: 219-24. [CrossRef]

2. De Luca F, Santucci S, Corica D, Pitrolo E, Romeo M, Aversa T. Hashimoto's thyroiditis in childhood: presentation modes and evolution over time. *Ital J Pediatr* 2013; 39: 8. [CrossRef]

3. Lee SJ, Lim GY, Kim JY, Chung MH. Diagnostic performance of thyroid ultrasonography screening in pediatric patients with a hypothyroid, hyperthyroid or euthyroid goiter. *Pediatr Radio* 2016; 46: 104-11. [CrossRef]

4. Marocchi C, Vitti P, Cetani F, Catalano F, Concetti R, Pinchera A. Thyroid ultrasonography helps to identify patients with lymphocytic thyroiditis who are prone to develop hypothyroidism. *J Clin Endocrinol Metab* 1991; 72: 209-13. [CrossRef]

5. Yoshida A, Adachi T, Noguchi T, Urabe K, Onoyama S, Okamura Y, et al. Echographic findings and histological feature of the thyroid: a reverse relationship between the level of echo-amplitude and lymphocytic infiltration. *Endocrinol Jpn* 1985; 32: 681-90. [CrossRef]

6. Müller HW, Schröder S, Schneider C, Seifert G. Sonographic tissue characterization in thyroid gland diagnosis. A correlation between sonography and histology. *Klin Wochenschr* 1985; 63: 706-10. [CrossRef]

7. Kim HG, Kim EK, Han KH, Kim H, Kwak JY Pathologic spectrum of lymphocytic infiltration and recurrence of papillary thyroid carcinoma. *Yonsei Med J* 2014; 55: 879-85. [CrossRef]

8. Kim GR, Kim EK, Kim SJ, Ha EJ, Yoo J, Lee HS, et al. Evaluation of Underlying Lymphocytic Thyroiditis With Histogram Analysis Using Grayscale Ultrasound Images. *J Ultrasound Med* 2016; 35: 519-26. [CrossRef]

9. Schiemann U, Avenhaus W, Konturek JW, Gellner R, Hengst K, Gross M. Relationship of clinical features and laboratory parameters to thyroid echogenicity measured by standardized grey scale ultrasonography in patients with Hashimoto's thyroiditis. *Med Sci Monit* 2003; 9: 13-7.

10. Kim SH, Park CS, Jung SL, Kang BJ, Kim JY, Choi JJ, et al. Observer variability and the performance between faculties and residents: US criteria for benign and malignant thyroid nodules. *Korean J Radiol* 2010; 11: 149-55. [CrossRef]

11. Park CS, Kim SH, Jung SL, Kang BJ, Kim JY, Choi JJ, et al. Observer variability in the sonographic evaluation of thyroid nodules. *J Clin Ultrasound* 2010; 38: 287-93. [CrossRef]

12. Erol B, Kara T, Gürses C, Karakoyun R, Köroğlu M, Süren D, et al. Gray scale histogram analysis of solid breast lesions with ultrasonography: can lesion echogenicity ratio be used to differentiate the malignancy? *Clini Imaging* 2013; 37: 871-5. [CrossRef]

13. Loy M, Cianchetti ME, Cardia F, Melis A, Boi F, Mariotti S, et al. Correlation of computerized gray-scale sonographic findings with thyroid function and thyroid autoimmune activity in patients with Hashimoto's thyroiditis. *J Clin Ultrasound* 2004; 32: 136-40. [CrossRef]

14. Acharya UR, Vinitha Sree S, Mookiah MR, Yantri R, Molinari F, Zielesnik W, et al. Diagnosis of Hashimoto's thyroiditis in ultrasound using tissue characterization and pixel classification. *Proc Inst Mech Eng H* 2013; 227: 788-98. [CrossRef]

15. Mazziotti G, Sorvillo F, Iorio S, Carbone A, Romeo A, Piscopo M et al. Gray-scale analysis allows a quantitative evaluation of thyroid echogenicity in the patients with Hashimoto thyroiditis. *Clin Endocrinol* 2003; 59: 223-29. [CrossRef]

16. Höfling DB, Cerri GG, Juliano AG, Marui S, Chammas MC. Value of thyroid echogenicity in the diagnosis of chronic autoimmune thyroiditis. *Radiol Bras* 2008; 41: 409-17. [CrossRef]

Cite this article as: Çekiç B, Mutlu İN, Parlak AE, Köksel Y, Erdem Toslak İ, Parlak M. B-Mode Gray Scale Histogram Value in Diagnosis of Adolescent Patients with Hashimoto Thyroiditis. *Istanbul Med J* 2017; 18: 222-6.