



Synchronous Partial Intestinal Malrotation and Duodenojejunal Junction Adenocarcinoma: An Unusual Clinical Presentation

Senkronize Parsiyel İntestinal Malrotasyon ve Duodenojejunal Bileşke Adenokarsinomu: Olağan Dışı Bir Klinik Tablo

Metin Yalaza¹, Mehmet Tolga Kafadar², Ahmet Türkan³, Aydın İnan⁴

Abstract / Öz

Intestinal malrotation is the result of an abnormal physiological herniation of the midgut during embryo development. Since there exists a number of different malrotation types, the diagnosis of this condition is challenging. Concurrent intestinal malrotation and duodenojejunal junction cancer is extremely rare. Here we present the case of a 71-year-old patient who underwent segmental resection for duodenojejunal junction adenocarcinoma that concurrently presented with small bowel malrotation.

Keywords: Duodenojejunal junction, intestinal malrotation, adenocarcinoma

Intestinal malrotasyon embriyogenik dönemde orta barsağın fizyolojik herniasyonu sırasında meydana gelir. Malrotasyonların, farklı formlarından dolayı tanısı oldukça zordur. İntestinal malrotasyon ve eş zamanlı duodenojejunal bileşke kanseri birlikteliği olan hastalar son derece nadirdir. Bu yazıda duodenojejunal bileşke kanseri nedeniyle segmental rezeksiyon yapılan ve eş zamanlı ince barsak malrotasyonu bulunan 71 yaşında bir hasta sunuldu.

Anahtar Kelimeler: Duodenojejunal bileşke, intestinal malrotasyon, adenokarsinom

Introduction

Asymmetrical but normal arrangement of organs within the chest and abdomen is known as situs solitus. Situs inversus is a congenital abnormality wherein the main visceral organs are located in the opposite or mirror positions of their original positions. Situs viscerum inversus totalis is the most common form wherein all visceral organs are translocated around the sagittal plane, and it affects 1 of every 4000–5000 live births. Situs viscerum inversus partialis occurs more rarely and affects a single or a number of internal organs. Although all organs in the abdominal cavity may be affected, cases with only intestinal transposition have also been reported (1). Here we report a seldom encountered case of concurrent duodenojejunal junction adenocarcinoma and partial intestinal malrotation.

Case Report

A 71-year-old female presented with complaints of weight loss of 20 kg and a 1-year history of intermittent abdominal pain, nausea, and nonbloody emesis. Her medical history was significant for type 2 diabetes mellitus, hypertension, and peptic ulcer disease. Physical examination was unremarkable and laboratory tests on admission were as follows: red blood cell count, 4.85×10^{12} cells/L; hemoglobin level, 13.7 g/dL; hematocrit, 41.9%; leukocyte count, 14.2×10^9 cells/L (63.6% neutrophils); platelet count, 264×10^9 cells/L; urea level, 92 mg/dL; creatinine level, 1.3 mg/dL; AST level, 56 U/L; ALT level, 145 U/L; amylase level, 129 IU/L; and glucose level, 111 mg/dL. The serum levels of CA 19-9, CEA, and ferritin were 23.32 (normal <37) U/mL, 0.73 (normal: 0.1–6.5) ng/mL, and 335.2 (normal: 35–150) ng/mL, respectively. Abdominal computed tomography identified stenosis of the duodenojejunal junction and dilation of the duodenum in addition to intestinal malrotation with the small bowel in the right abdomen (Figure 1). We detected and biopsied a circumferential fungating lesion involving the fourth part of the duodenum and reaching the ligament of Treitz on upper gastrointestinal endoscopy (Figure 2). Biopsy findings were consistent with those of adenocarcinoma of small intestinal origin. Laparotomy was performed because of the diagnosis of malignant intestinal neoplasm, and it revealed a stenosing adenocarcinoma at the duodenojejunal junction with dilation of the duodenum (Figure 3). During routine abdominal exploration, a condition of intestinal malrotation was observed; the duodenojejunal flexure was found to be on the right side of the median plane instead of the left. Oncological segmental resection of the duodenojejunal tumor with the regional mesentery was performed. Intestinal continuity was then restored by end-to-side anastomosis. Pathological examination of the surgical specimen revealed T3N2M0 small bowel adenocarcinoma, with the greatest diameter of the tu-

¹Clinic of General Surgery (Surgical Oncology), Health Sciences University Ankara Numune Training and Research Hospital, Ankara, Türkiye

²Clinic of General Surgery, Health Sciences University Mehmet Akif İnan Training and Research Hospital, Şanlıurfa, Türkiye

³Clinic of General Surgery, Dr. Münif İslamoğlu State Hospital, Kastamonu, Türkiye

⁴Clinic of General Surgery, Ankara Umut Hospital, Ankara, Türkiye

Address for Correspondence

Yazışma Adresi:
Mehmet Tolga Kafadar
E-mail: drtolgakafadar@hotmail.com

Received/Geliş Tarihi: 24.11.2016

Accepted/Kabul Tarihi: 07.02.2017

© Copyright 2017 by Available online at
www.istanbulmedicaljournal.org

© Telif Hakkı 2017 Makale metnine
www.istanbultipdergisi.org web sayfasından
ulaşılabilir.

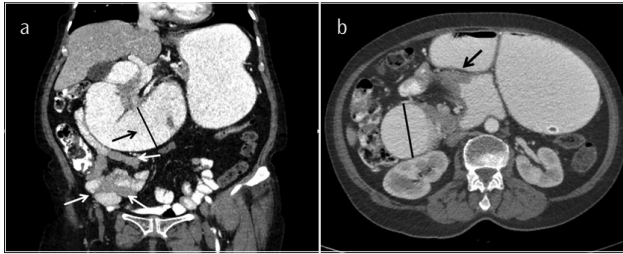


Figure 1. a, b. (a) Malrotation is seen in CT findings. Jejunal segment of the small bowel is located on the right side of the abdomen (white arrows). Duodenal segments are enlarged (black arrow and straight line). (b) Duodenojejunal junction is located on the right side to the mid-line. Arrow shows the duodenojejunal junction tumor. Duodenal segment enlargement due to the obstruction of this lesion is seen on CT (straight line)

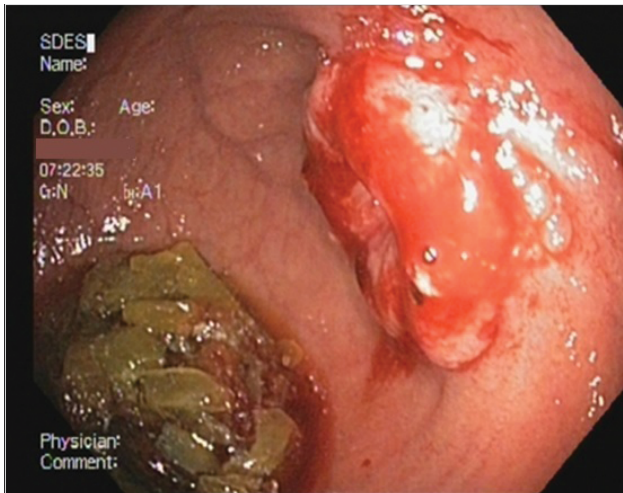


Figure 2. Endoscopic image of the duodenojejunal junction neoplasm

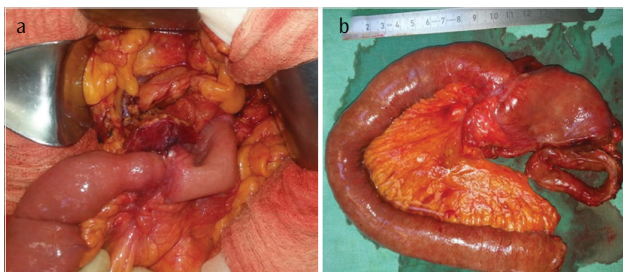


Figure 3. a, b. (a) Intraoperative photograph of a duodenojejunal tumor indicating the stricture. (b) Specimen with stenosis

mor being 2 cm and showing invasion into the serosa. The resected margins were clear. Of the 12 lymph nodes collected, four were positive for metastatic carcinoma and showed invasion through the lymphatic capsule. The patient had no problem during the postoperative period and was discharged 7 days later. Informed consent was obtained from the patient.

Discussion

Small bowel cancer accounting for only 1% gastrointestinal neoplasms is a rare entity that is increasing in incidence in the past few decades. Adenocarcinoma of the small intestine is a rare type of gastrointestinal neoplasm and typically involves the distal duodenum and proximal jejunum.

Only a limited number of cases have been reported on the association of malrotation, incomplete rotation, and reverse rotation with cancer. This is the first case report on small bowel cancer associated with intestinal malrotation. Normal intestinal embryology was first described by Meckel in 1817 (2). In 1923, Dott (3) described the relationship between the anatomy and clinical outcomes for malrotation. In 1936, Ladd (4) wrote the classic article on the treatment of malrotation, and his surgical approach (i.e., Ladd procedure) remains the cornerstone of practice till today. Roughly speaking, any deviation from the normal 270° counterclockwise rotation of the midgut during embryologic life is defined as intestinal malrotation. Midgut malrotation in adults is rare and its approximate incidence has been reported to be 0.19%. Incidental diagnoses may occur in adulthood during cadaveric study or during imaging investigations and surgery for unrelated pathology. It is a finding on 1 in 500 gastrointestinal contrast studies (5). Frazer and Robbins (6) described the process of rotation and fixation in three stages. The stage of midgut development denominates the different subtypes of this anomaly, namely incomplete rotation, non-rotation, or reverse rotation. Incomplete rotation (or classic malrotation) is 90°–180° counterclockwise rotation in the foregut–midgut and midgut–hindgut junctions. This limited rotation results in the failure of the duodenojejunal limb to rotate posterior and to the left of the superior mesenteric artery, incomplete rotation of the cecocolic limb, and close proximity of the fixation points for the proximal and distal midgut mesentery. Arrest of development along this limited rotation also results in the lack of ligament of Treitz or one that lies to the right of the spine as in our case. Our patient seems to have had a form of incomplete rotation with the small intestine on the right side of the abdomen. Non-rotation, or minimal (<90°) rotations, occurring in the primitive gut junctions around the superior mesenteric artery results in the absence of ligament of Treitz, absence of lateral cecal fixation, and variable proximity between the proximal and distal midgut mesentery. Reverse rotation is rare and results in the partial clockwise rotation of the foregut–midgut junction anterior to the superior mesenteric artery. While malrotation is by definition a condition of the intestines, alterations in anatomic configuration also apply to the mesentery and, as result, to the mesenteric vessels. The most frequently encountered (>60% of all malrotation cases collectively) vascular variants include the inverse arteriovenous relationship and vertical vascular positioning. An awareness of intestinal malrotation with accompanying vascular variants is critical to perform resection in malrotated patients so as not to cause bowel necrosis. Devascularization of the short segmental end arteries that supply the small intestine may ensue when a surgeon fails to note that the superior mesenteric artery has an anomalous location, that is to the left of the superior mesenteric vein (7). Kawahara et al. (8) reported a case of cancer of the ampulla of Vater accompanied by malrotation. According to Kawahara et al. (8) an understanding of vascular variants is critical when performing pancreaticoduodenectomy in malrotated patients. Michalopoulos et al. (9) reported the case of a patient with colon cancer and intestinal malrotation. That paper stressed that it was of paramount significance to have a knowledge of the existence of a malrotation prior to surgery, both for better planning of the operation and minimizing operative complication rate. Brillantino et al. (10) reported a case of colon cancer complicated by anomalies of intestinal rotation and fixation. They stated that anomalies of the vascular and lymphatic system associated with intestinal malrotation dictate the strategy of a surgeon treating an associated colon carcinoma.

Conclusion

We are of the opinion that our report provides a fine, albeit anatomically challenging, example of an oncologically effective and correct procedure performed to treat small bowel cancer accompanying intestinal malrotation. Familiarity with the concept of isolated, complete, or partial rotation of the midgut is critical to successful performance of the procedure in malrotated patients.

Informed Consent: Verbal informed consent was obtained from patients who participated in this study.

Peer-review: Externally peer-reviewed.

Author Contributions: Concept - M.Y., M.T.K.; Design - M.Y., M.T.K., A.T.; Supervision - M.Y., M.T.K., A.İ.; Resources - M.Y., M.T.K., A.T.; Materials - M.Y., A.T., A.İ.; Data Collection and/or Processing - M.Y., M.T.K., A.İ.; Analysis and/or Interpretation - M.Y., M.T.K., A.İ.; Literature Search - M.Y., M.T.K.; Writing Manuscript - M.Y., M.T.K.; Critical Review - M.T.K., A.İ.

Conflict of Interest: No conflict of interest was declared by the authors.

Financial Disclosure: The authors declared that this study has received no financial support.

Hasta Onamı: Sözlü hasta onamı bu çalışmaya katılan hastalardan alınmıştır.

Hakem Değerlendirmesi: Dış bağımsız.

Yazar Katkıları: Fikir - M.Y., M.T.K.; Tasarım - M.Y., M.T.K., A.T.; Denetleme - M.Y., M.T.K., A.İ.; Kaynaklar - M.Y., M.T.K., A.T.; Malzemeler - M.Y., A.T., A.İ.; Veri Toplanması ve/veya İşlemesi - M.Y., M.T.K., A.İ.; Analiz ve/veya Yorum - M.Y., M.T.K., A.İ.; Literatür Taraması - M.Y., M.T.K.; Yazıyı Yazan - M.Y., M.T.K.; Eleştirel İnceleme - M.T.K., A.İ.

Çıkar Çatışması: Yazarlar çıkar çatışması bildirmemişlerdir.

Finansal Destek: Yazarlar bu çalışma için finansal destek almadıklarını beyan etmişlerdir.

References

1. Torretta A, Zeri KP, Mascaqni D, Panzini A, Papetti MT, Peparini N, et al. Traditional colectomy in a patient with situs viscerum inversus partialis. *G Chir* 1999; 20: 293-5.
2. Meckel JF. Biedungsgeschichte des Darmkanals der Säugethiere und namentlich des Menschen. *Deutsches Archiv für die Physiologie*; Vol. III Part I, 1817.
3. Dott NM. Anomalies of intestinal rotation: Their embryology and surgical aspects: With report of five cases. *Br J Surg* 1923; 11: 251-86. [\[CrossRef\]](#)
4. Ladd WE. Surgical diseases of the alimentary tract in infants. *N Engl J Med* 1936; 215: 705-8. [\[CrossRef\]](#)
5. Gemmell A. Partial malrotation of the bowel in an adult patient presenting with abdominal pain. *BMJ Case Rep* 2015; 2015.
6. Frazer JE, Robbins RH. On the factors concerned in causing rotation of the intestine in man. *J Anat Physiol* 1915; 50: 74-110.
7. Zengin A, Uçar Bİ, Düzgün ŞA, Bayhan Z, Zeren S, Yaylak F, et al. Adult midgut malrotation presented with acute bowel obstruction and ischemia. *Int J Surg Case Rep* 2016; 22: 5-7. [\[CrossRef\]](#)
8. Kawahara R, Horiuchi H, Nogita H, Akashi M, Mikagi K, Yoshitomi M, et al. A case of cancer of the ampulla of Vater accompanied by malrotation. *Kurume Med J* 2013; 60: 33-6. [\[CrossRef\]](#)
9. Michalopoulos A, Papadopoulos V, Paramythiotis D, Papavramidis T, Douros V, Netta S, et al. Colonic cancer in a patient with intestinal malrotation: a case report. *Tech Coloproctol* 2010; 14: S65-6.
10. Brillantino A, Marano L, Schettino M, Torelli F, Izzo G, Cosenza A, et al. Report of a rare case of colon cancer complicated by anomalies of intestinal rotation and fixation: a case report. *Cases Journal* 2009; 2: 6555. [\[CrossRef\]](#)