



# A Child with 3p Deletion Syndrome Who Recovered from Influenza-Related Acute Respiratory Distress Syndrome

## 3p Delesyonu Sendromu Tanılı Bir Çocukta, İnfluenza İlişkili Akut Solunum Sıkıntısı Sendromu

Gürkan Atay<sup>1</sup>, Gülşah Kavrul<sup>2</sup>, Manolya Acar<sup>3</sup>, Murat Sütçü<sup>3</sup>, Kemal Nişli<sup>1</sup>, Ayper Somer<sup>3</sup>

### Abstract / Öz

Influenza virus can cause serious complications, especially in patients with comorbid illnesses. Acute respiratory distress syndrome (ARDS) is among the most common causes of influenza-related morbidity and mortality. Herein we present the case of a boy with a genetic disorder who recovered from influenza-related ARDS. A 3-year-old boy with 3p deletion syndrome was admitted for refractory cough and fever. During his follow-up, sudden respiratory failure concomitant with ARDS occurred. He was transferred to the pediatric intensive care unit (PICU) and intubated. Broad-spectrum antibiotherapy and oseltamivir were administered. Nazopharyngeal swab polymerase chain reaction (PCR) analysis revealed H1N1. Ventilation parameters were set according to that recommended for ARDS. On the ninth day of his admission, the patient was discharged from PICU. Appropriate ventilation strategies together with early oseltamivir therapy improves outcomes of influenza-related ARDS.

**Keywords:** Influenza, acute respiratory distress syndrome, oseltamivir

Influenza virüsü, özellikle kronik hastalığı olanlarda ciddi komplikasyonlara yol açmaktadır. Akut respiratuar distress sendromu (ARDS), influenza ilişkili morbidite ve mortalite nedenlerinin başında gelmektedir. Burada genetik sendrom nedeniyle takipli olup, influenza ilişkili ARDS başarı ile tedavi edilen bir çocuk olgu sunulmuştur. 3p delesyonu sendromu tanılı, üç yaşında erkek hasta öksürük ve ateş nedeni ile yatırıldı. İzlemi sırasında ani solunum sıkıntısı ve ARDS gelişti. Yoğun bakım ünitesine transfer edilen hasta entübe edildi. Geniş spektrumlu antibiyoterapi ve oseltamivir başlandı. Ventilator parametreleri ARDS önerileri doğrultusunda ayarlandı. Nazofarengeal sürüntünün polimeraz zincir reaksiyonu incelemesinde influenza A/H1N1 pozitifliği saptandı. Hasta YBÜ yatışının 9.gününde ekstübe edildi. Erken oseltamivir tedavisi ve uygun ventilator stratejileri influenza ilişkili ARDS tedavisinde başarı şansını arttırmaktadır.

**Anahtar Kelimeler:** Influenza, akut respiratuar distress sendromu, oseltamivir

## Introduction

Influenza virus, mainly the H1N1 type, presents with various types of respiratory system involvement and may lead to acute respiratory distress syndrome (ARDS). Patients with neurogenetic disorders are more prone to complications of influenza because they have diminished lung capacity secondary to decreased muscle tone, deterioration of innate protective mechanisms of the respiratory tract, immunosuppression caused by malnutrition, and comorbid congenital defects (1). Chromosome 3p deletion syndrome is a rare chromosomal abnormality that occurs at the end of the short arm of chromosome 3 (2). Clinical features depend on the exact size and location of the deletion, but most common features are low birth weight, microcephaly, trigonocephaly, hypotonia, psychomotor and growth retardation, ptosis, telecanthus, downslanting palpebral fissures, micrognathia, and feeding problems. The incidence of congenital heart disease and renal abnormalities is also increased. Respiratory failure is the most common cause of morbidity and mortality in such patients. We hereby present the case of a boy with 3p deletion syndrome who recovered from ARDS secondary to H1N1.

## Case Report

A 3-year-old male patient presented to our Pediatric Emergency Unit with a history of refractory cough and fever for a duration of 5 days. He had bilateral fine crackles on auscultation and pneumatic infiltrations on chest radiography (Figure 1). He was born to a first-cousin marriage with a 3p deletion syndrome. He had been admitted to the hospital several times and once to the pediatric intensive care unit (PICU) because of aspiration pneumonia. The patient was internalized to the Infectious Disease Inpatient Service with a diagnosis of pneumonia and was administered ceftriaxone. On the fourth day of admission, acute respiratory failure occurred, and he was transferred to PICU. He had a fever of 39°C, and his respiratory rate was 40/min with intercostal and subcostal retractions. Bilateral fine crackles were heard on auscultation. The results of cardiovascular examination and echocardiographic test were normal. He was intubated because of hypoxic respiratory failure and was ventilated with synchronized intermittent mandatory ventilation pressure support mode. Chest radiography showed diffuse bilateral ground-glass opacities in the lung parenchyma (Figure 2a). The partial pressure of arterial oxygen / fraction of inspired oxygen PaO<sub>2</sub>/FiO<sub>2</sub> ratio was <100, which was in concordance with ARDS.

<sup>1</sup>Division of Pediatric Intensive Care, Istanbul University Istanbul School of Medicine, Istanbul, Türkiye

<sup>2</sup>Department of Pediatrics, Istanbul University Istanbul School of Medicine, Istanbul, Türkiye

<sup>3</sup>Division of Pediatric Infectious Diseases, Istanbul University Istanbul School of Medicine, Istanbul, Türkiye

### Address for Correspondence

Yazışma Adresi:

Manolya Acar

E-mail: manolya\_kara@yahoo.com

Received/Geliş Tarihi: 08.08.2017

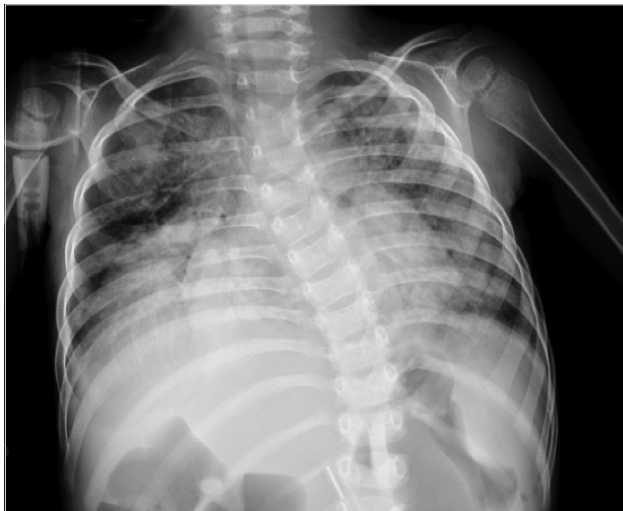Accepted/Kabul Tarihi: 08.03.2017

© Copyright 2017 by Available online at www.istanbulmedicaljournal.org

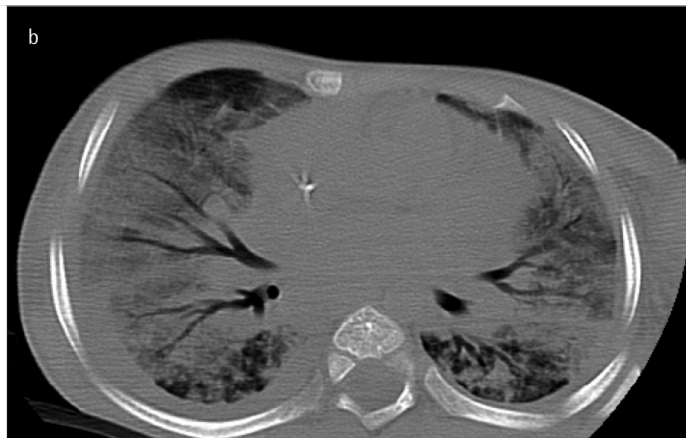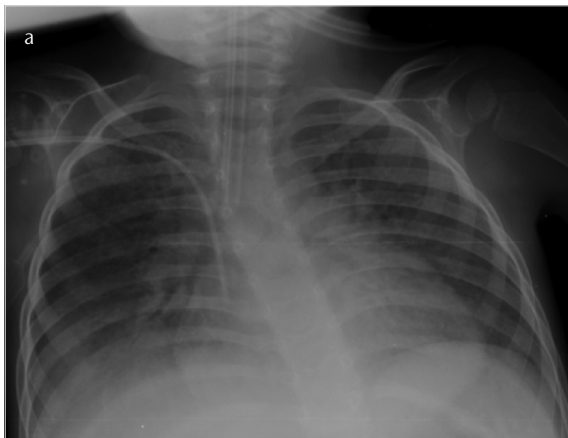
© Telif Hakkı 2017 Makale metnine www.istanbultipdergisi.org web sayfasından ulaşılabilir.

Laboratory examinations revealed bicytopenia together with slightly increased leukocyte count [white blood cell count, 13410/mm<sup>3</sup> (65% neutrophils, 30% lymphocytes); hemoglobin, 8.5 g/dL; platelet, 102900/mm<sup>3</sup>]. Results of the routine blood chemistry tests were within normal limits. C-reactive protein level was 85 mg/L (normal, <5 mg/L), and procalcitonin level was 0.5 ng/mL (normal, <0.05 ng/mL). He was started on broad-spectrum antibiotic therapy, including piperacillin–tazobactam (200 mg/kg/day) and teicoplanin (10 mg/kg/day). Fentanyl and midazolam infusions were initiated for sedation. Because effective ventilation could not be achieved, rocuronium was administered for neuromuscular blockade. Acute onset of respiratory failure raised the suspicion of possible influenza virus, and the patient was started on oseltamivir therapy on the same day of PICU admission.

Bronchoalveolar lavage fluid was negative for acid-fast bacilli. Ventilator parameters were set to positive end-expiratory pressure (PEEP) of 10 cmH<sub>2</sub>O, positive inspiratory pressure of 29 cmH<sub>2</sub>O, and respiratory rate of 38 bpm. The patient was intermittently switched to the prone position. Intensive respiratory physiotherapy and timely suctioning was performed. The patient was started on meropenem instead of piperacillin-tazobactam because of persistent fever. Computed tomography of the chest was in concordance with ARDS (Figure 2b). Enteral feeding was administered



**Figure 1.** Chest X-ray on admission



**Figure 2. a, b.** Results of chest X-ray (a) and chest computed tomography (b) consistent with ARDS

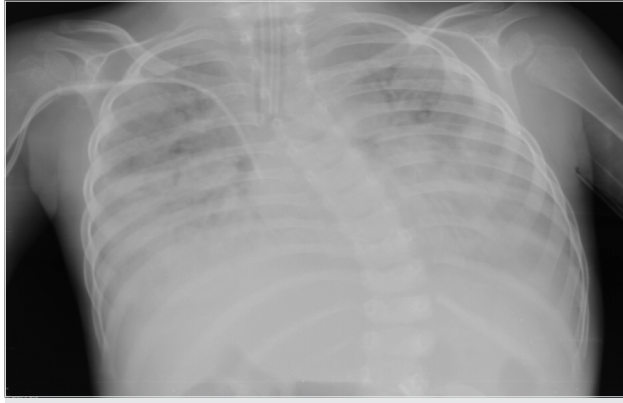
over percutaneous endoscopic gastrostomy tube and was gradually increased in amount. Negative fluid balance was targeted. He was administered erythrocyte suspension because of anemia. Nasopharyngeal swab sample polymerase chain reaction analysis (Fast-track Diagnostics Ltd. Malta, Qiagen, Germany) was positive for H1N1. A seven-day course of oseltamivir was administered. On the seventh day of admission, his chest X-ray showed significant improvement (Figure 3). Ventilation parameters were gradually reduced, and he was extubated on the ninth day. After extubation, respiratory physiotherapy was performed every 3 h. On the 11<sup>th</sup> day of admission, the patient was discharged from PICU. Written informed consent was obtained from the patient's parents.

## Discussion

Acute respiratory distress syndrome is an acute inflammatory syndrome, which has a high mortality rate worldwide. Diffuse alveolar damage, increased vascular permeability, and injury to the source of surfactant results in hypoxemia. The identified risk factors for ARDS are sepsis, aspiration of gastric contents, trauma, pneumonia, fractures, and disseminated intravascular coagulopathy, but there are insufficient data to evaluate age-dependent differences in the pathophysiology (3-5).

Influenza infections during childhood usually present as mild upper respiratory tract disease, but severe complications like ARDS can also occur, especially in patients with underlying chronic conditions. According to H1N1 pandemic influenza data, 0.3% of the population developed H1N1-related illness and were hospitalized and 20% of hospitalized patients required ICU care (6). It has also been reported that among PICU admissions, neurological disorders were the most common chronic diseases (7). Chronic pulmonary disease, preterm birth, cardiac malformations, obesity, genetic disorders, and immunocompromising conditions constitute the other causes. Similarly, our patient was diagnosed with 3p deletion syndrome and had experienced several episodes of pneumonia earlier.

H1N1-related respiratory illnesses in the pediatric population include the following: viral pneumonitis; exacerbations of asthma or chronic pulmonary disease; and exacerbations of other underlying diseases, such as congestive heart failure, secondary bacterial pneumonia, and croup/bronchiolitis. Among those, viral pneumonitis is the most common cause of ICU admission (5). The majority of these



**Figure 3.** Chest X-ray on the seventh day of treatment

patients presented with rapidly progressive hypoxemia and bilateral alveolar infiltrates on chest radiograph, which were consistent with ARDS (8). For the definition of ARDS, symptoms of hypoxemia must occur within 7 days (9). Chest imaging findings of new infiltrates must be consistent with acute pulmonary parenchymal disease, and oxygenation index (OI) or  $\text{PaO}_2/\text{FiO}_2$  (P/F ratio) must reveal hypoxemia. OI is preferred for patients treated with invasive mechanical ventilation. For treatment of ARDS, higher PEEP levels, lower tidal volume, and permissive hypercapnia are targeted. This combination has been shown to be effective in optimizing lung recruitment and limiting barotrauma, with improved survival (3, 5, 10). In our patient, we also preferred higher PEEP levels, which were titrated to achieve arterial oxygen saturation between 88–97 mmHg. The maximum PEEP and tidal volume applied to our patient were 10  $\text{cmH}_2\text{O}$  and 8–10 mL/kg, respectively. Although high-frequency ventilation is not mandatory, chest physiotherapy and neuromuscular blockade are recommended if necessary (3). Therefore, we performed routine chest physiotherapy and neuromuscular blockade and supplied ventilation with synchronized pressure support mode in our patient. Although it is not routinely recommended, we performed intermittent prone positioning and achieved effective ventilation. The influence of prone position on the improvement of oxygenation is unclear. It may recruit the dorsal regions of the lungs, which remain atelectatic in supine position and may also optimize removal of secretions and postural drainage (11).

In our patient, we used empiric broad-spectrum antibiotics because of the high levels of infection markers, and oseltamivir phosphate was added to the treatment on the second day of admission. A meta-analysis has demonstrated that early oseltamivir treatment (within 2 days of symptom onset) compared with later oseltamivir treatment was associated with a reduction in the mortality risk (12). Oseltamivir treatment was initiated in our patient before the nasal swab results were obtained. We believe that our patient's early recovery with the exception of all other supportive treatments was related to this early antiviral medication.

## Conclusion

Influenza-related ARDS can lead to increased morbidity and mortality. Appropriate ventilation strategies together with early antiviral treatment improves outcomes.

**Informed Consent:** Written and verbal informed consent were obtained from the patient's parents who participated in this study.

**Peer-review:** Externally peer-reviewed.

**Author Contributions:** Concept - G.A., M.A.; Design - G.K.; Supervision - K.N., A.S.; Resources - M.A.; Materials - G.A.; Data Collection and/or Processing - M.S.; Analysis and/or Interpretation - K.N., A.S.; Literature Search - M.A.; Writing Manuscript - M.A., G.K.; Critical Review - K.N., A.S.

**Conflict of Interest:** No conflict of interest was declared by the authors.

**Financial Disclosure:** The authors declared that this study has received no financial support.

**Hasta Onamı:** Yazılı ve sözlü hasta onamı bu çalışmaya katılan hastanın ailesinden alınmıştır.

**Hakem Değerlendirmesi:** Dış bağımsız.

**Yazar Katkıları:** Fikir - G.A., M.A.; Tasarım - G.K.; Denetleme - K.N., A.S.; Kaynaklar - M.A.; Malzemeler - G.A.; Veri Toplanması ve/veya İşlemesi - M.S.; Analiz ve/veya Yorum - K.N., A.S.; Literatür Taraması - M.A.; Yazıyı Yazan - M.A., G.K.; Eleştirel İnceleme - K.N., A.S.

**Çıkar Çatışması:** Yazarlar çıkar çatışması bildirmemişlerdir.

**Finansal Destek:** Yazarlar bu çalışma için finansal destek almadıklarını beyan etmişlerdir.

## References

- Kumar A, Zarychanski R, Pinto R, Cook DJ, Marshall J, Lacroix J, et al. Critically ill patients with 2009 influenza A(H1N1) infection in Canada. *JAMA* 2009; 302: 1872-9. [CrossRef]
- Available from: <http://www.omim.org/entry/61379>
- Jouvet P, Thomas NJ, Wilson DF, Erickson S, Khemani R, Zimmerman J, et al. Pediatric Acute Lung Injury Consensus Conference Group. Pediatric acute respiratory distress syndrome: consensus recommendations from the Pediatric Acute Lung Injury Consensus Conference. *Pediatr Crit Care Med* 2015; 16: 428-39. [CrossRef]
- Cheifetz IM. Pediatric Acute Respiratory Distress Syndrome. *Respir Care* 2011; 56: 1589-99. [CrossRef]
- Streng A, Prifert C, Weissbrich B, Liese JG; Bavarian PICU Study Group on Influenza and Other Viral ARI. Continued high incidence of children with severe influenza A(H1N1) admitted to paediatric intensive care units in Germany during the first three post-pandemic influenza seasons, 2010/11–2012/13. *BMC Infect Dis* 2015; 15: 573. [CrossRef]
- Rice TW, Rubinson L, Uyeki TM, Vaughn FL, John BB, Miller RR, et al. Critical Illness from 2009 Pandemic Influenza A (H1N1) Virus and Bacterial Co-Infection in the United States. *Crit Care Med* 2012; 40: 1487-98. [CrossRef]
- Millman AJ, Finelli L, Bramley AM, Peacock G, Williams DJ, Arnold SR, et al. Community-Acquired Pneumonia Hospitalization among Children with Neurologic Disorders. *J Pediatr* 2016; 173: 188-95. [CrossRef]
- Estenssoro E, Ríos FG, Apezteguía C, Reina R, Neira J, Ceraso DH, et al. Pandemic 2009 influenza A in Argentina: a study of 337 patients on mechanical ventilation. *Am J Respir Crit Care Med* 2010; 182: 41-8. [CrossRef]
- Ranieri VM, Rubenfeld GD, Thompson BT, Ferguson ND, Caldwell E, Fan E, et al. Acute Respiratory Distress Syndrome The Berlin Definition. *JAMA* 2012; 307: 2526-2533.
- Petrucci N, Iacovelli W. Lung protective ventilation strategy for the acute respiratory distress syndrome. *Cochrane Database Syst Rev* 2007; 3: CD003844.
- Lamm WJ, Graham MM, Albert RK. Mechanism by which the prone position improves oxygenation in acute lung injury. *Am J Respir Crit Care Med* 1994; 150: 184-93. [CrossRef]
- Muthuri SG, Venkatesan S, Myles PR, Leonardi-Bee J, Al Khuwaitir TS, Al Mamun A, et al. Effectiveness of neuraminidase inhibitors in reducing mortality in patients admitted to hospital with influenza A H1N1pdm09 virus infection: a meta-analysis of individual participant data. *Lancet Respir Med* 2014; 2: 395-404. [CrossRef]