

# Minimally Invasive Excision of a Rare Cricoid Chondroma: Case Report

## *Nadir Görülen Krikoid Kondromanın Minimal İnvaziv Eksizyonu: Olgu Sunumu*

Suat BİLİCİ,<sup>1</sup> Ümit TAŞKIN,<sup>2</sup> Özgür YİĞİT,<sup>1</sup> Ayşe Pelin GÖR,<sup>1</sup> Semiha BATTAL HAVARE<sup>3</sup>

### SUMMARY

Laryngeal chondromas are very rare cartilaginous benign tumors of the larynx. The cricoid cartilage is most usually involved. We present a large cricoid cartilage chondroma obstructing the laryngeal passage without vocal cord paralysis. A fifty-six-year-old man presented with severe dyspnea that had developed over a period of 2-3 weeks. Endoscopic laryngeal examination revealed a subglottic rough mass almost totally obstructing the airway. Computed tomography and magnetic resonance imaging revealed a 3×4 cm mass, which completely obstructed the subglottis. The lesion was totally excised with segmental excision of posterior cricoid cartilage. The laryngeal function was preserved. Our case shows that in well-circumferentiated lesions, minimal invasive surgery may yield a properly functioning larynx without any recurrence.

**Key words:** Dyspnea; chondroma; cricoid cartilage.

### ÖZET

Kondrom larenksin nadir görülen kartilajinöz bir benign tümörüdür. Krikoid kartilaj en sık olarak etkilenir. Bu yazıda, vokal kord paralizi yapmadan larengeal pasajı tıkayan büyük bir krikoid kartilaj kondromu olgusu sunuldu. Elli altı yaşında erkek hasta 2-3 hafta içinde gelişen ciddi dispne ile başvurdu. Endoskopik larengeal muayenede havayolunu tamamına yakın tıkayan subglottik kitle görüldü. Bilgisayarlı tomografi ve manyetik rezonans görüntüleme ile 3x4 cm'lik subglottisi tamamen tıkayan kitle görüldü. Segmental posterior krikoid kartilaj rezeksiyonu ile lezyon tamamen eksize edildi. Larenks fonksiyonları korundu. Olgumuz göstermiştir ki, iyi sınırlanmış kondromların tedavisinde minimal invaziv cerrahi ile nüks oluşmadan, iyi fonksiyon gösteren bir larenks sağlamak mümkündür.

**Anahtar sözcükler:** Dispne; kondrom; krikoid kartilaj.

### INTRODUCTION

Laryngeal chondromas are very rare cartilaginous benign tumors of the larynx.<sup>[1]</sup> They occur in the elderly, with a peak incidence in the 7th decade. The cricoid cartilage is most usually involved. Chondromas are rare in the thyroid cartilage, arytenoids, epiglottis, and hyoid bone.<sup>[2]</sup> Differential diagnosis of laryngeal chondromas include subglottic tumors, chondrosarcoma, adenocarcinoma, advanced squamous cell carcinoma, amyloid tumor, chondrometaplasia, granular cell myoblastoma, semilemmoma, plasmacytoma, and metastatic tumors.<sup>[3]</sup>

Treatment of chondromas requires surgical excision. However, high recurrences of the disease occur because of incomplete resection. Cricoid chondromas usually require segmental resection of the cricoid cartilage with tumor excision or even total laryngectomy.

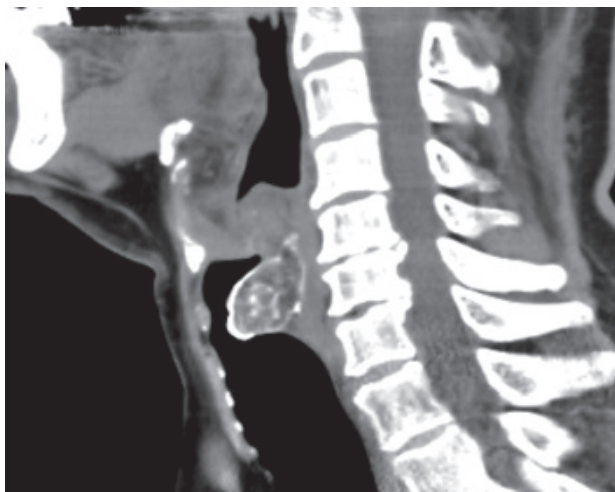Here we present a large cricoid cartilage chondroma obstructing the laryngeal passage without vocal cord paralysis. We excised the chondroma totally via a laryngofissure approach to preserve laryngeal function.

Submitted (Geliş tarihi): 03.02.2011 Accepted (Kabul tarihi): 20.05.2011

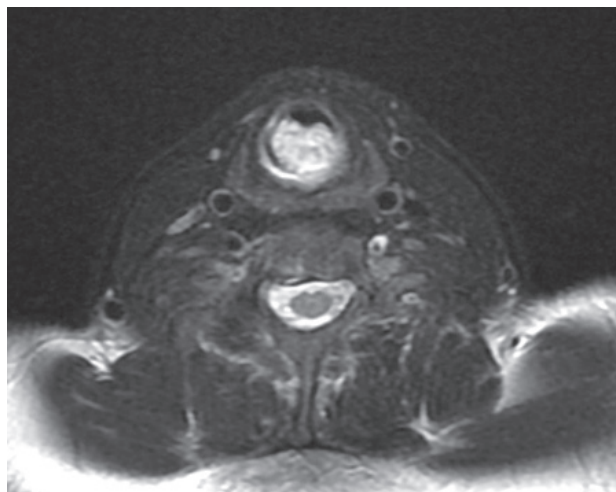
<sup>1</sup>2nd Department of Otorhinolaryngology, and <sup>3</sup>Pathology, Istanbul Training and Research Hospital, Istanbul

<sup>2</sup>Department of Otorhinolaryngology, Bağcılar Training and Research Hospital, Istanbul

Correspondence (İletişim): Suat Bilici, M.D. e-mail (e-posta): suatbilici@yahoo.com



**Fig. 1.** Preoperative view of the lesion on the cricoid cartilage (CT).



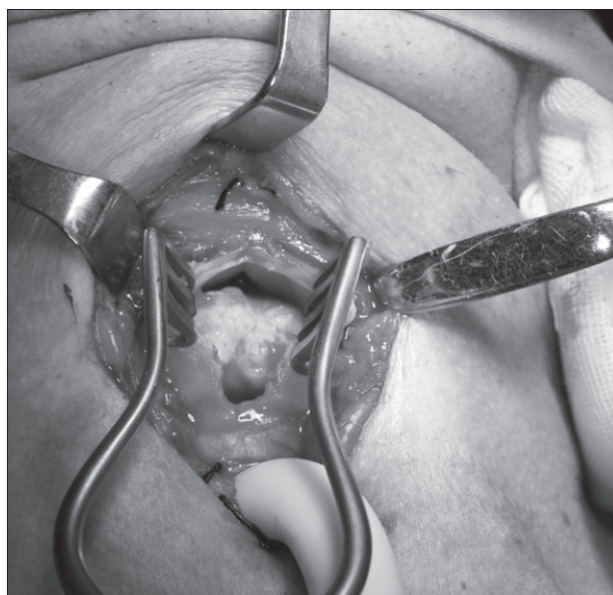
**Fig. 2.** Preoperative view of the lesion on the cricoid cartilage (MRI).

### CASE REPORT

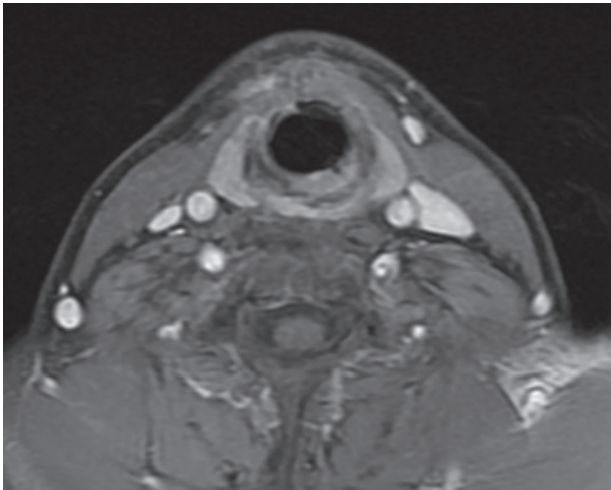
A fifty-six-year-old man presented with severe dyspnea that had developed over a period of 2-3 weeks. He had difficulty in swallowing. He had no voice problem. He had been prescribed various medical treatments for dyspnea and swallowing difficulty. However, his symptoms worsened in the days prior to the application. At the time of presentation, he appeared cyanotic and experienced wheezing during inspiration and expiration,

as well as severe dyspnea. Endoscopic laryngeal examination revealed a subglottic rough mass almost totally obstructing the airway. The vocal cords were mobile bilaterally. There was no mass in the neck region. An emergency tracheotomy was performed. After clearing the airway, a radiological evaluation was conducted. Computed tomography and magnetic resonance imaging revealed a 3×4 cm mass, which completely obstructed the subglottis (Fig. 1,2).

The lesion appeared to give no evidence of sur-



**Fig. 3.** Intraoperative appearance of the cricoid cartilage chondroma.



**Fig. 4.** Postoperative view. No recurrence (MRI).

rounding tissue invasion representing as chondroma. The lesion was exposed via a laryngofissure incision made anteriorly and excision was undertaken (Fig. 3).

It originated in the posterior section of the cricoid cartilage protruding through the laryngeal passage. Approximately 90% of the subglottic region was obstructed by the tumor. The lesion was totally excised with segmental excision of posterior cricoid cartilage. The lesion was smooth, expansive and firm with gritty calcifications and revealed chondroma or chondrosarcoma on macroscopic examination. Histopathological sections showed mature lobules of hyaline cartilage showing foci of myxoid degeneration. On the third postoperative day, the patient was decanulated without any complication. The laryngeal function was preserved. There was no recurrence of the tumor one year postoperatively (Fig. 4).

## DISCUSSION

Patients with cricoid chondroma present with slowly progressive dyspnea, hoarseness, dysphagia, and stridor.<sup>[4]</sup> Due to similar symptoms, they are usually misdiagnosed as having asthma,<sup>[4]</sup> as was the case in this instant. As chondromas are slow growing, benign cartilaginous tumors, symptoms may present from a week to a few years before diagnosis.<sup>[4]</sup> Differential diagnosis of chondroma from chondrosarcoma is difficult, and diagnosis of the tumor with biopsy is not certain. The exact diagnosis is based on clinical,

histological, and radiological data. In cricoid tumors, conservative treatment through laryngofissure is possible when the tumor involves less than half of the cartilage.<sup>[3]</sup> Conservative surgery is preferable. Laser endoscopic surgical excision of laryngeal cartilagenous tumors have been also described.<sup>[5]</sup> Although there is a high risk of recurrence, this does not compromise survival, and recurrences can be treated by local resection. However, excessive resection of the cricoid will adversely affect the laryngeal support and require reconstruction to prevent compromise of the airway. Therefore, total laryngectomy is usually the treatment of choice.<sup>[6]</sup> Various techniques permit complete resection and restoration of all laryngeal function in lesions involving less than 50% of the cricoid.<sup>[7]</sup>

There was no vocal cord paralysis in our case. We, therefore, preferred to excise the lesion via a laryngofissure approach to avoid injury to the recurrent laryngeal nerve at the cricothyroid junction. The protrusion of lesion through the larynx obstructed the lumen of the laryngeal passage. In contrast to the literature, the postcricoid section was not involved, enabling us to excise the lesion totally by preserving the stabilization cricoid or larynx. There was no need for reconstruction.

In conclusion, the laryngeal chondromas are benign, slow growing tumors, surgeons tend to avoid total resection of tumors requiring reconstruction of the larynx or total laryngectomy. Therefore, recurrences are common due to incomplete excision. However, our case shows that in well-circumscribed lesions, minimal invasive surgery may yield a properly functioning larynx without any recurrence.

## REFERENCES

1. O'Reilly RC, Elford BR. Imaging quiz case 1. Grade 1 chondrosarcoma (CS) of the larynx. *Arch Otolaryngol Head Neck Surg* 2000;126:1266, 1270-1.
2. Thomé R, Thomé DC, de la Cortina RA. Long-term follow-up of cartilaginous tumors of the larynx. *Otolaryngol Head Neck Surg* 2001;124:634-40.
3. Baatenburg de Jong RJ, van Lent S, Hogendoorn PC. Chondroma and chondrosarcoma of the larynx. *Curr Opin Otolaryngol Head Neck Surg* 2004;12:98-105.
4. Thompson LD, Gannon FH. Chondrosarcoma of the larynx: a clinicopathologic study of 111 cases

- with a review of the literature. *Am J Surg Pathol* 2002;26:836-51.
5. Merrot O, Gleizal A, Poupart M, et al. Cartilaginous tumors of the larynx: endoscopic laser management using YAG/KTP. *Head Neck* 2009;31:145-52.
  6. Casiraghi O, Martinez-Madrigal F, Pineda-Daboin K, et al. Chondroid tumors of the larynx: a clinicopathologic study of 19 cases, including two dedifferentiated chondrosarcomas. *Ann Diagn Pathol* 2004;8:189-97.
  7. Rizzo S, Strinati F, Longari F, et al. Chondrosarcoma of the larynx: presentation of a case and review of the literature. *Tumori* 2008;94:864-8.